

Hair Transplantation


Dr. Srikanth V

MBBS; MS; FRCS(Edin); FRCS(Glasg); MCh; DNB

Senior Consultant Plastic & Cosmetic Surgeon
Manipal Hospital
Clinique Belle

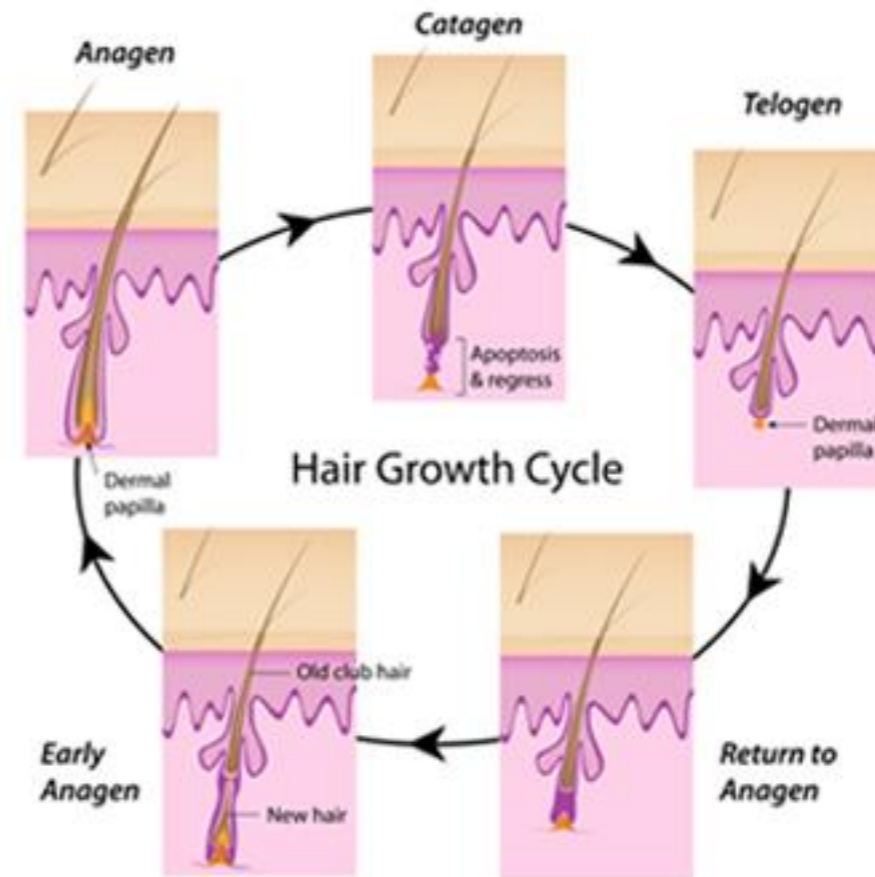
Hair Transplantation

- Hair transplantation is a surgical solution for Baldness



Life cycle of a hair follicle


- Anagen - growth
- Catagen - loss
- Telogen - resting



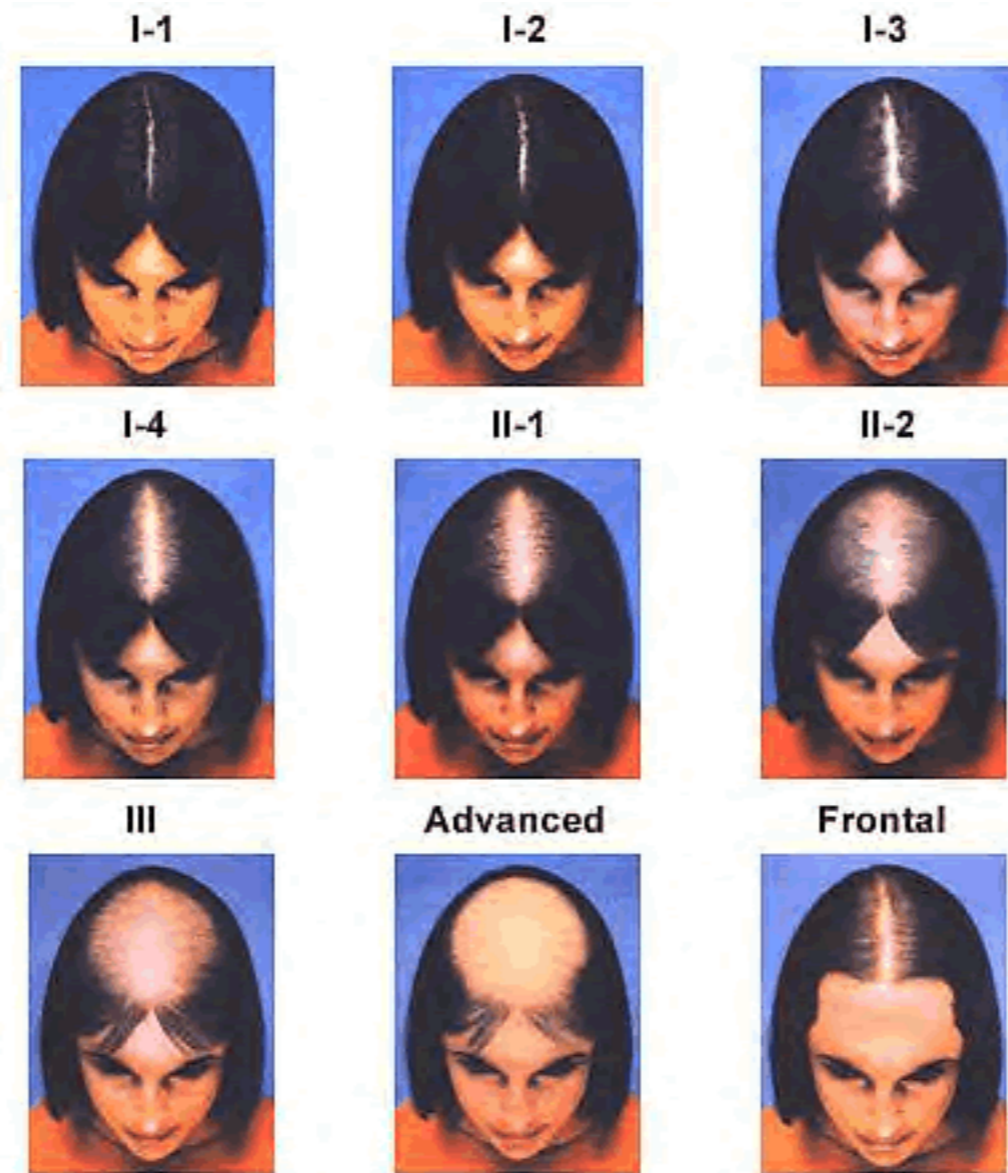
Causes of Hair loss

- Andro - genetic alopecia
- Cicatricial
- Medical illness

Norwood classification



Ludwig and Savin




Andro genetic Alopecia

- Has a combination of action of DHT and genetic factors
- **MOST COMMON**



Hair fall solutions

- Medical
- Surgical
- Camouflage
- Wigs



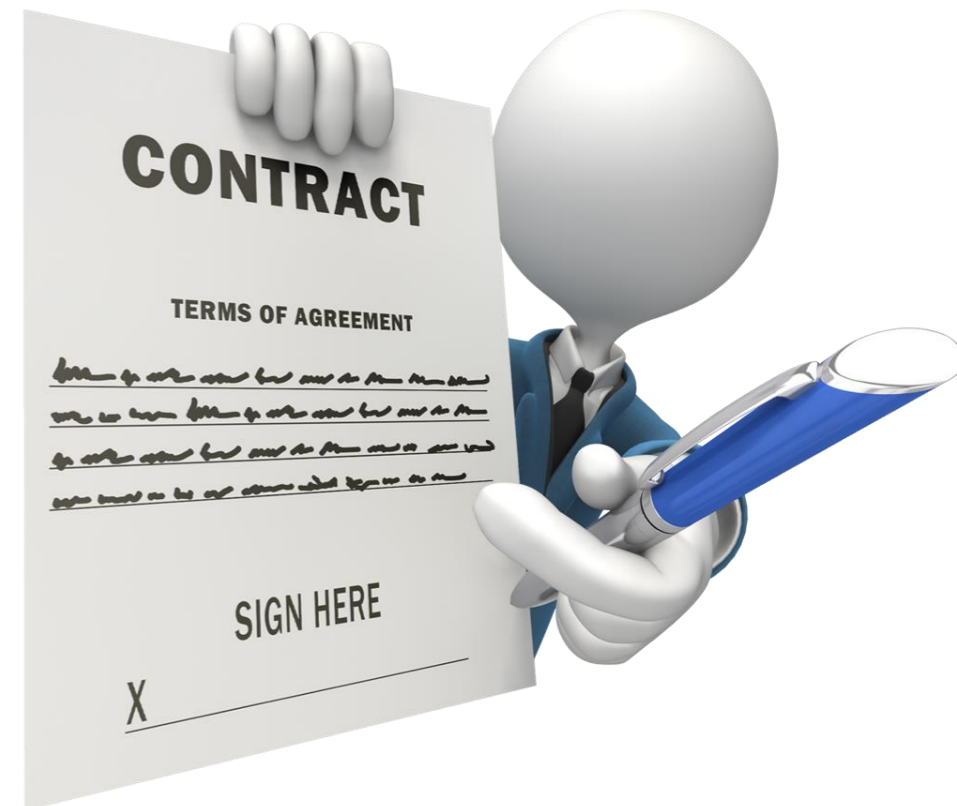Medical management

- Stimulants -
Minoxidil
- Anti androgens -
Finasteride
- Multi vitamins



Medical management Disadvantages

- Not everybody responds
- Needs discipline
- Lifelong
- Costs more than surgical treatment



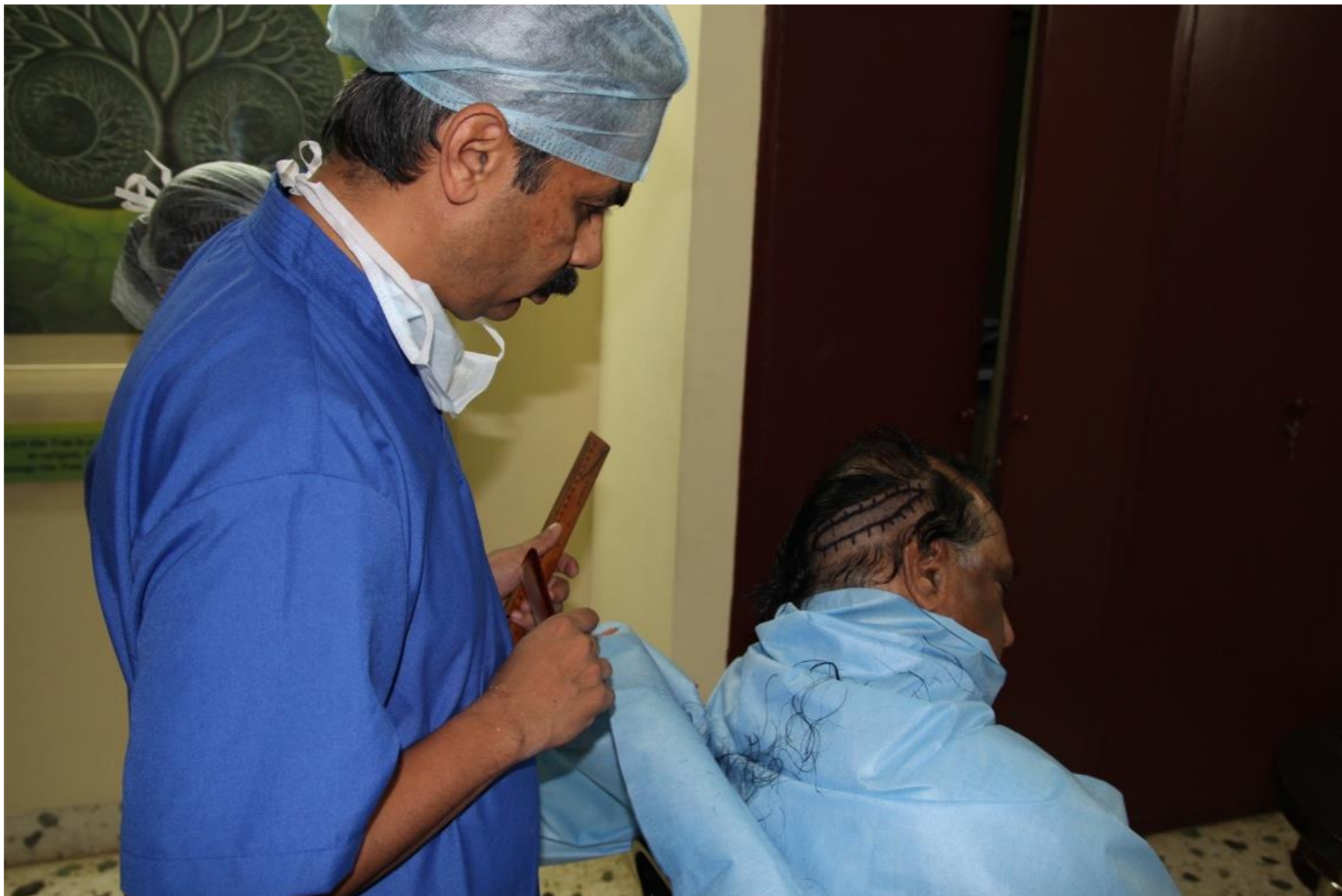Surgical treatment

- FUT
- FUE



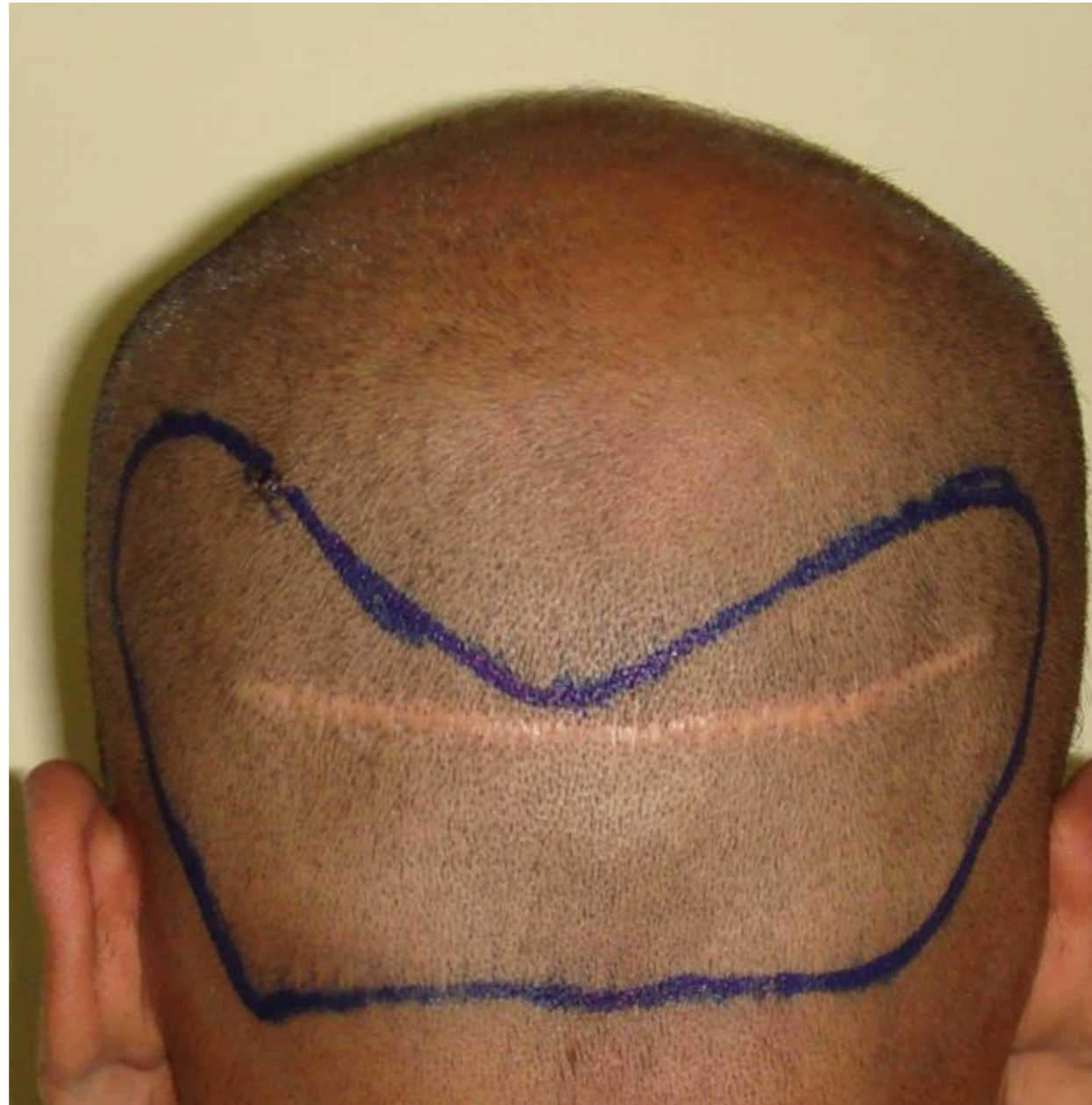FUT

- Strip is harvested from the “permanent zone” and the follicles are transplanted



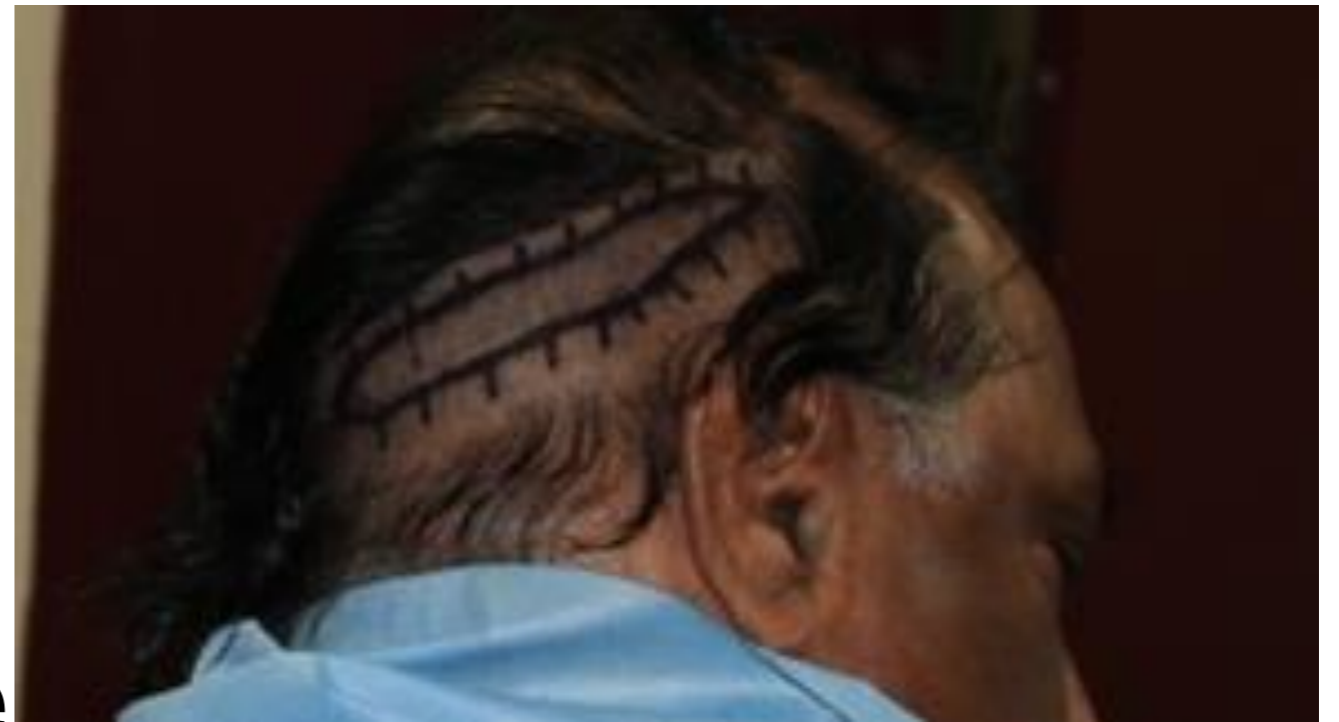FUE

- Individual follicles are harvested using a punch (manual or motorised)



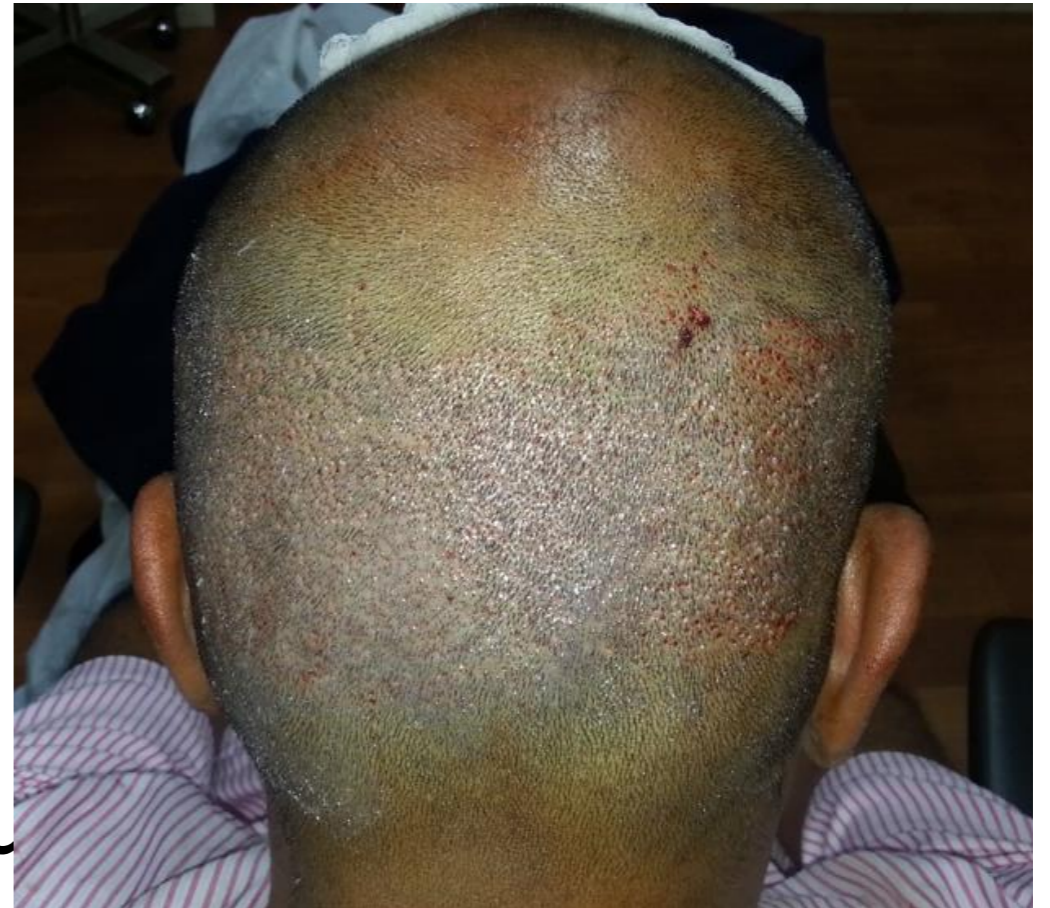FUT advantages

- Need not shave the entire scalp
- Second harvest may yield more graft
- Less work for the surgeon
- Less investment




FUE advantages

- No suture
- Well distributed scar
- Better acceptance
- Less Post op pain
- Can shave head in future



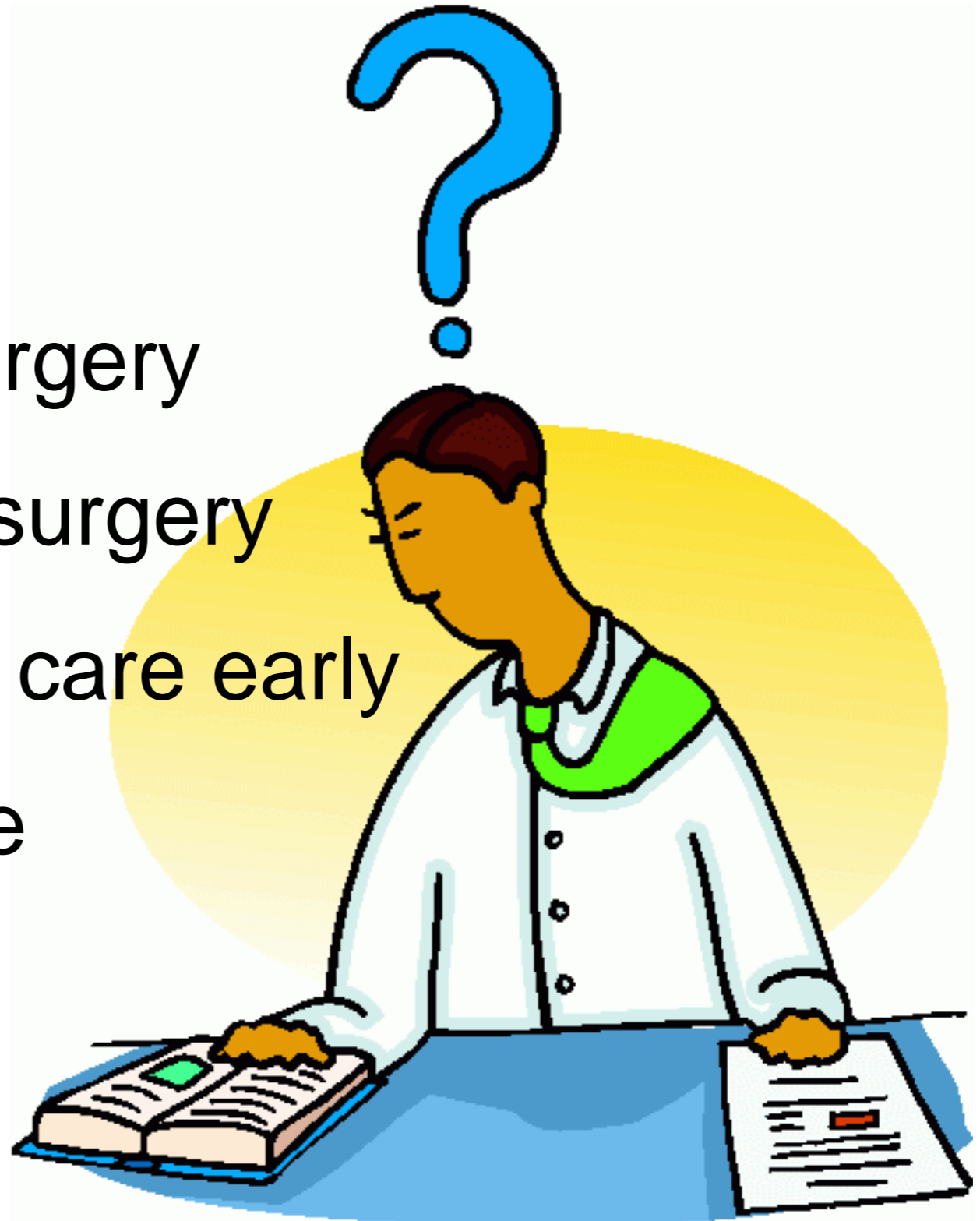Factors to consider

- Donor site
- Type of harvest
- Hairline design
- Implantation
- Post op care



Procedure

- Day prior to surgery
- On the day of surgery
- Post operative care early
- Late scalp care



Day prior to surgery

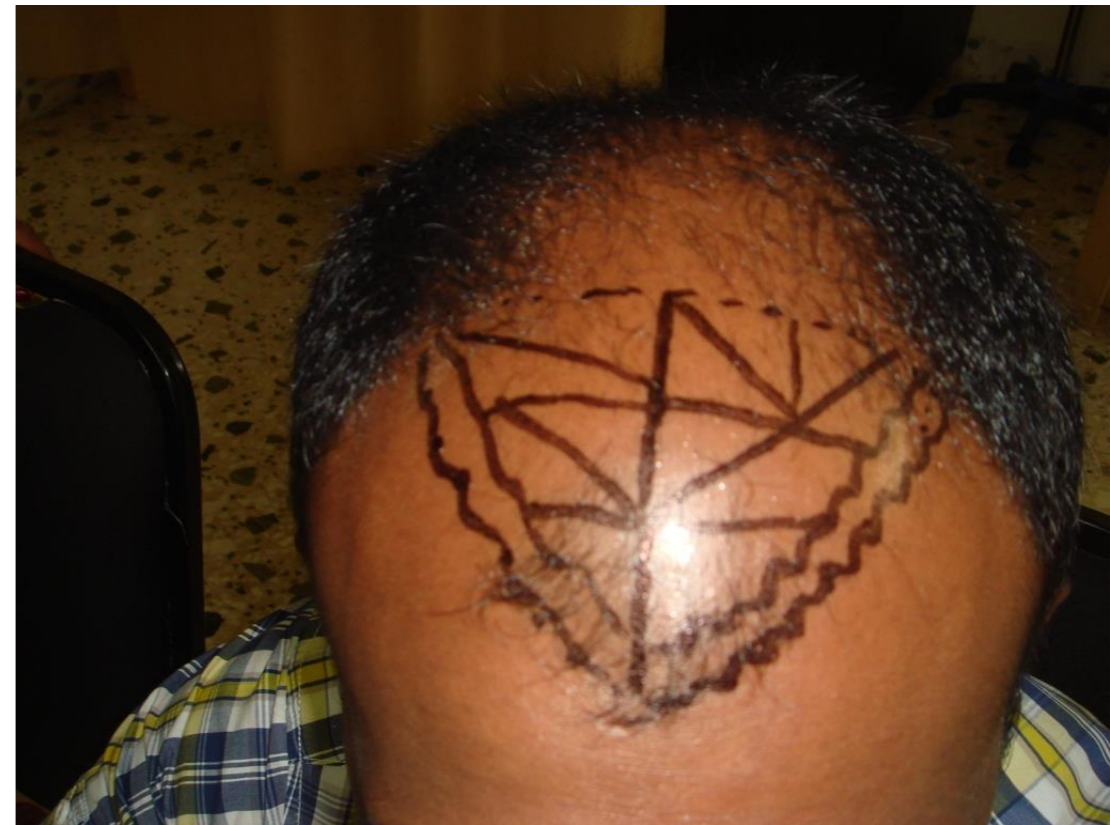- Assess fitness
- Marking
- Photography
- Preparation
- Consent

Consent

- Name of the surgeon
- Name of the procedure
- Signature of patient
- Witness
- Explain risks
- No guarantee other than your commitment

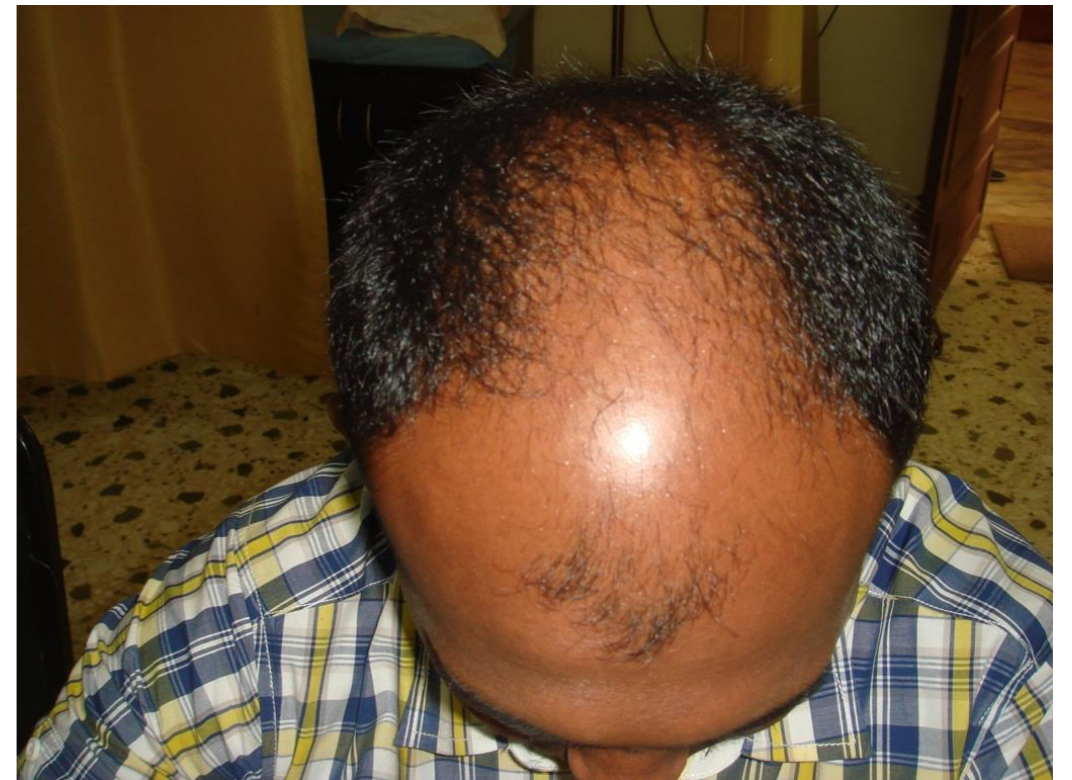Marking

- Sitting up
- Done before trimming of the hair
- Mark donor and recipient
- Patient to be actively involved in the recipient marking



Photography

- Well lit if not using flash
- Front, sides, top, back
- Standardize views for all patients



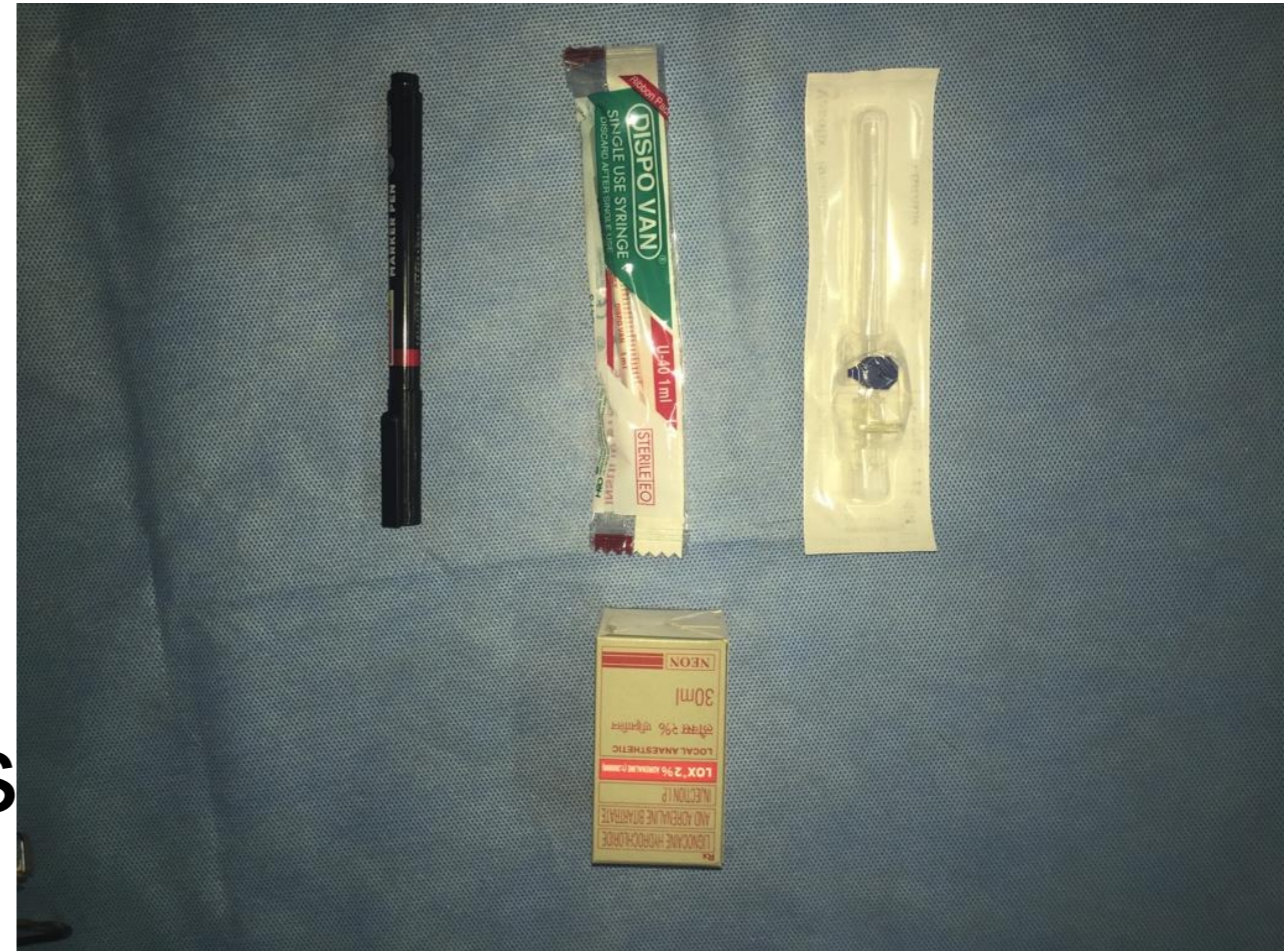Preperation

- Use a trimmer
- Prepare the entire scalp
- Confirm the marking
- Photograph the marking



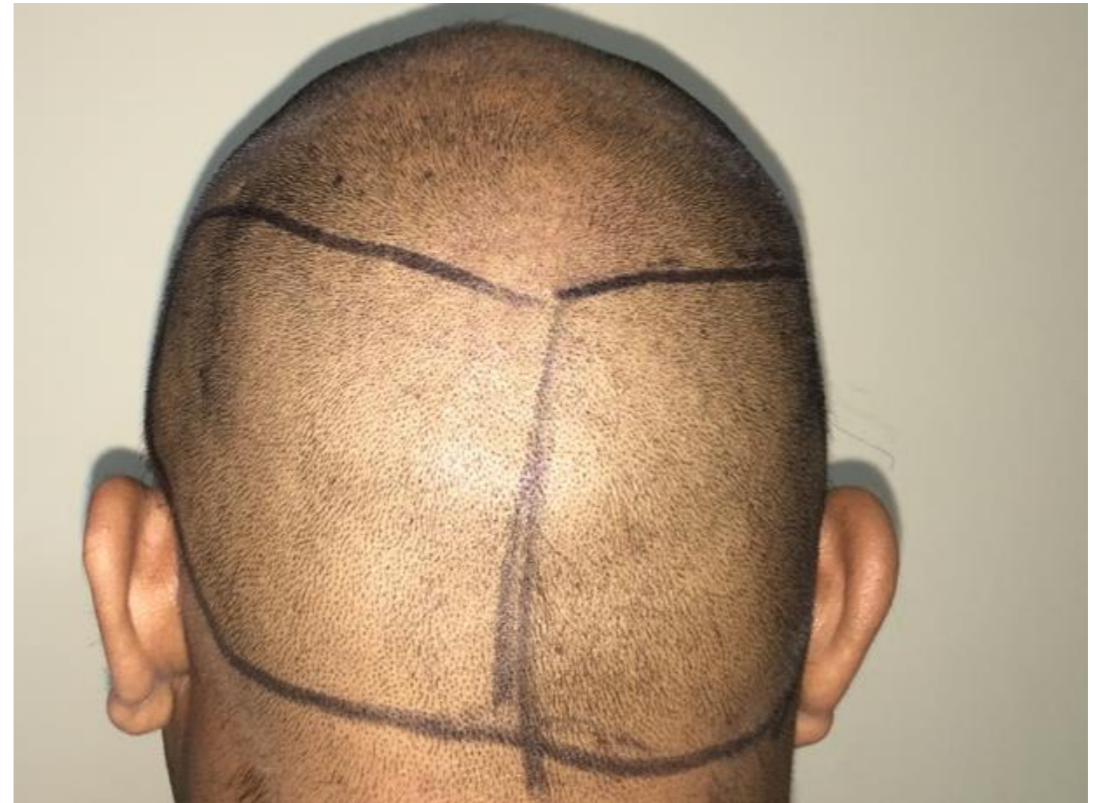On the day of surgery

- Marking
- IV line
- Lignocaine test dose



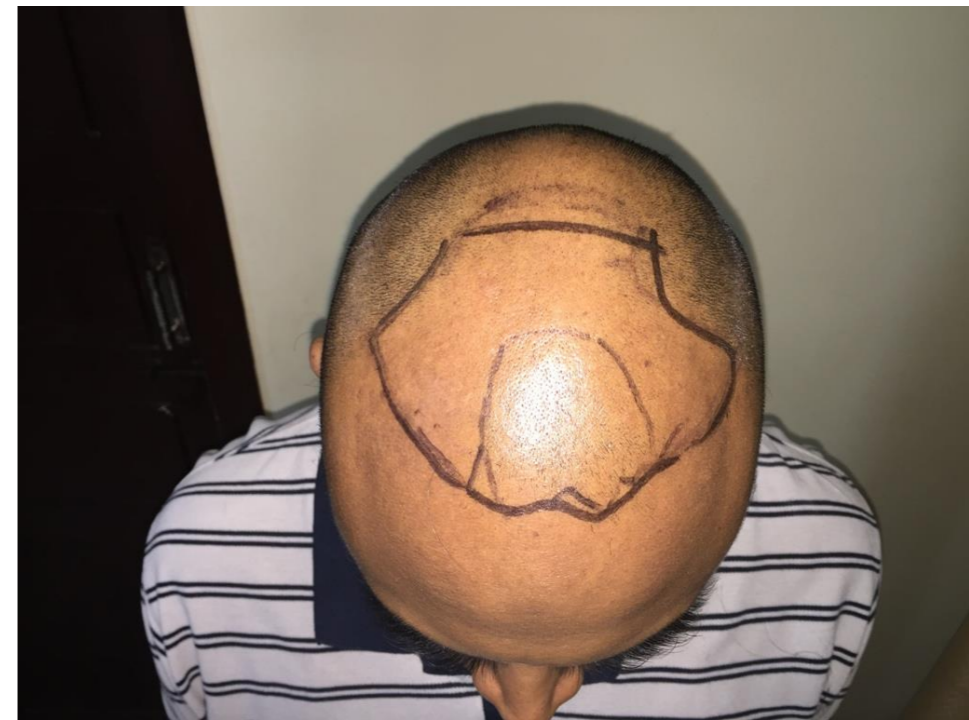
Marking donor site

- Do not cross to unsafe areas - near the pate, nape of neck, temporal region anteriorly
- Stick to the areas with good crop of hair



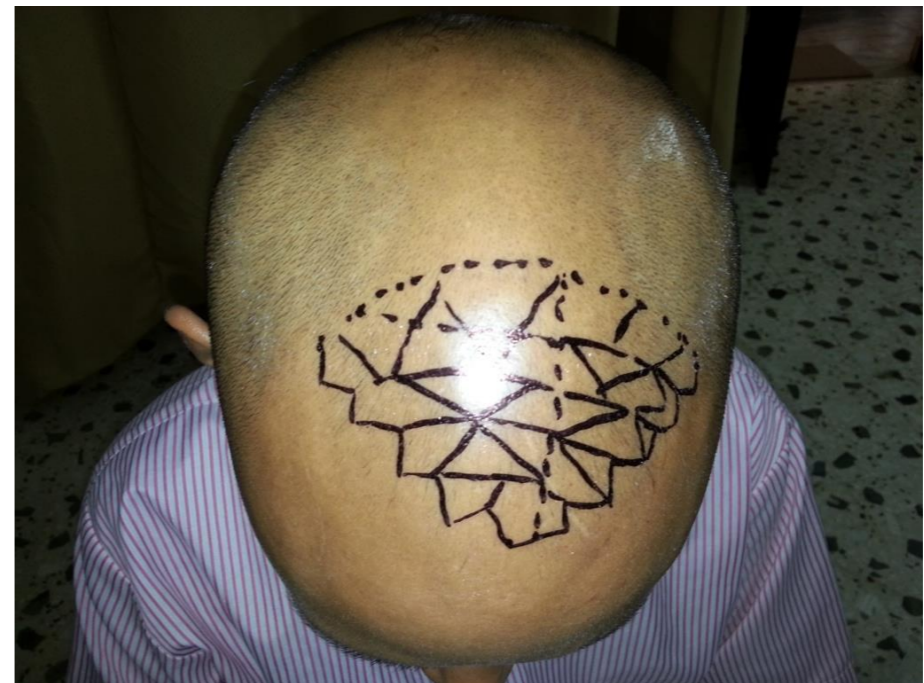Marking - recipient area

- Hair line
- Frontal tuft
- Temporal triangles



Recipient - Hairline

- Irregularly irregular triangles and tufts
- Single hair follicles
- Very acute to scalp
- Give a natural soft hairline



Recipient - Frontal tuft

- Dense Frontal tuft
- Local wears of early
- Implant in the centre asap

Recipient - Temporal triangles

- Gives appearance of full hair
- Are directed inferiorly
- Will use up lot of grafts

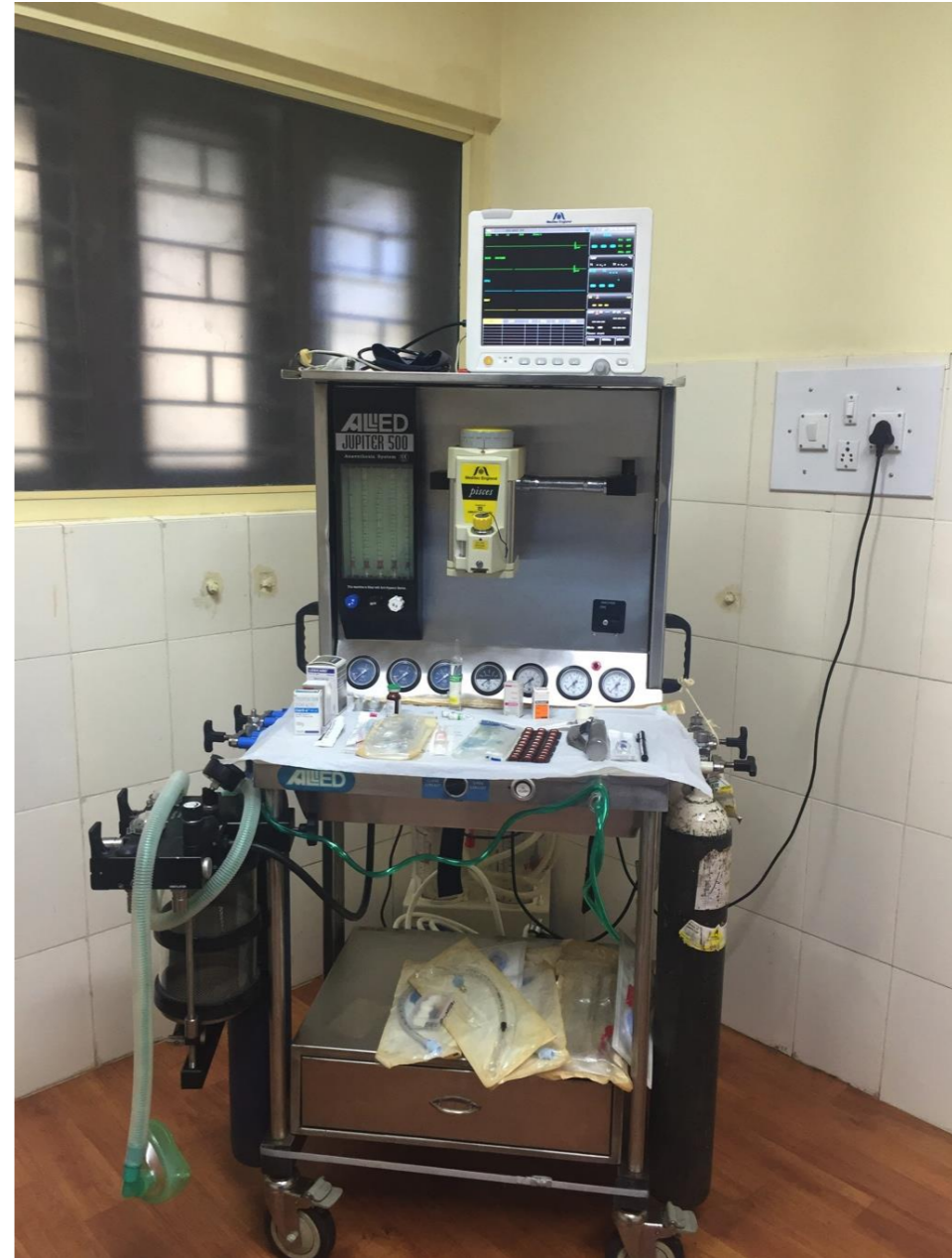Local Anaesthesia

- Dilute Bupivacaine
- Dilute Lignocaine
- Dilute adrenaline



Local Anaesthesia

- Do not cross the maximum recommended dose
- Be alert for any signs of reaction or toxicity
- Keep resuscitation equipment accessible and in working condition



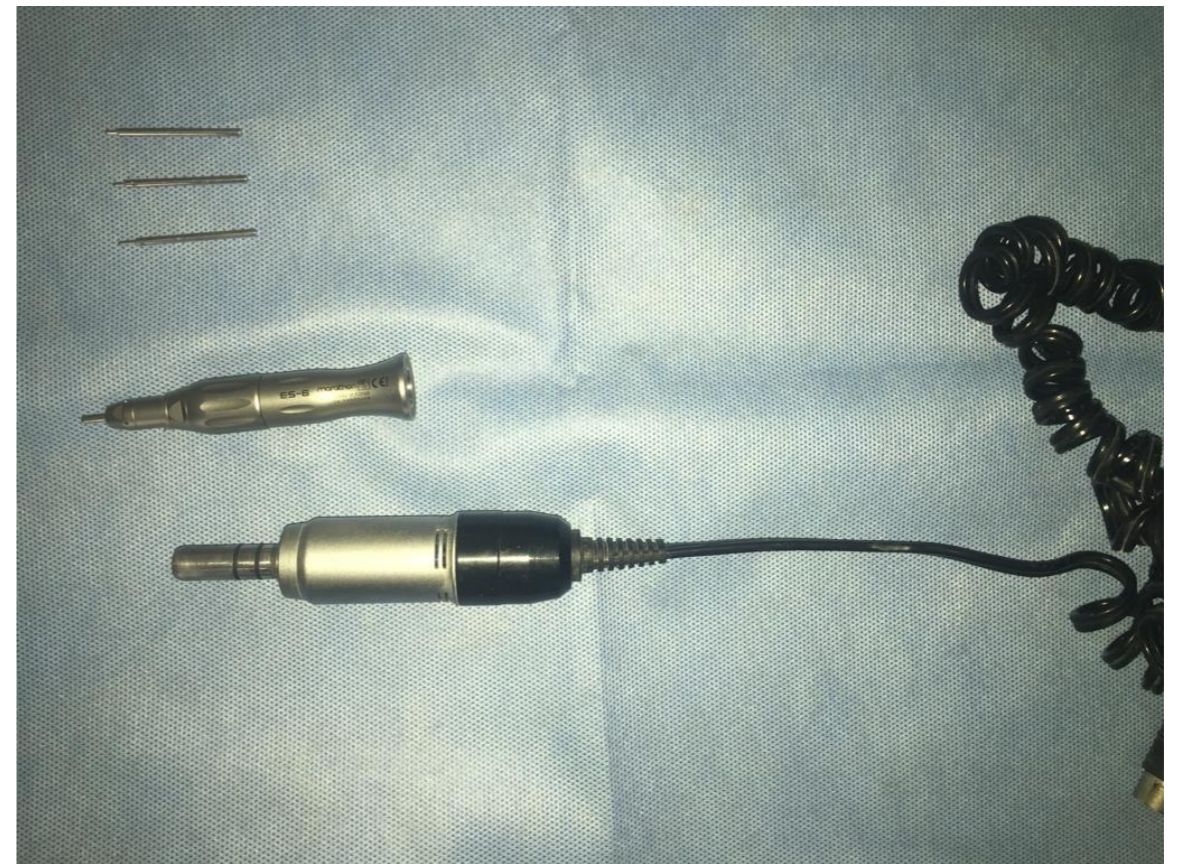
Giving local anaesthesia

- Use fine needles
- Tactile desensitization
- Ice
- Slow
- 20-30 mins

QuickTime™ and a
decompressor
are needed to see this picture.

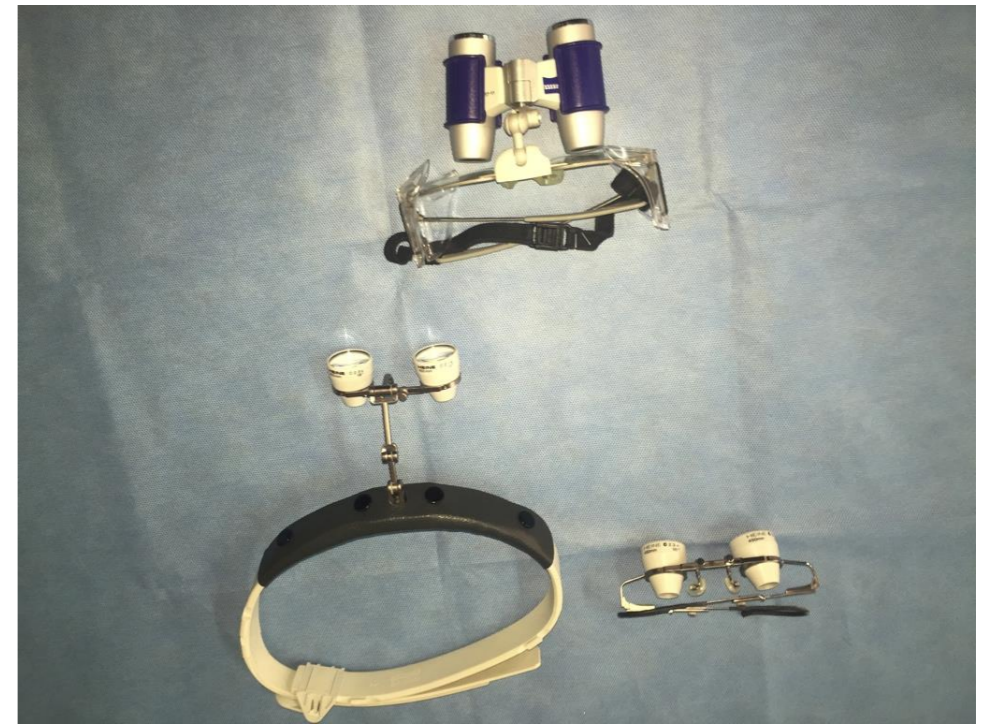Harvest

- Motorised
- 0.9 mm punches
- 3.5mm - 4.5mm
- Magnification -
loupes



Harvest

- Choose multi haired follicles
- Single follicles - hair line
- Harvest enough hair that you can implant the same session
- Test punch to test the angle of the follicles




Har

QuickTime™ and a
Apple Intermediate Codec decompressor
are needed to see this picture.

QuickTime™ and a
decompressor
are needed to see this picture.

Preparation of follicles

- Done by hair technicians
- Trim the epithelium around the follicle
- Preserve the root and sebaceous glands and errector pilori
- Magnification - microscopes



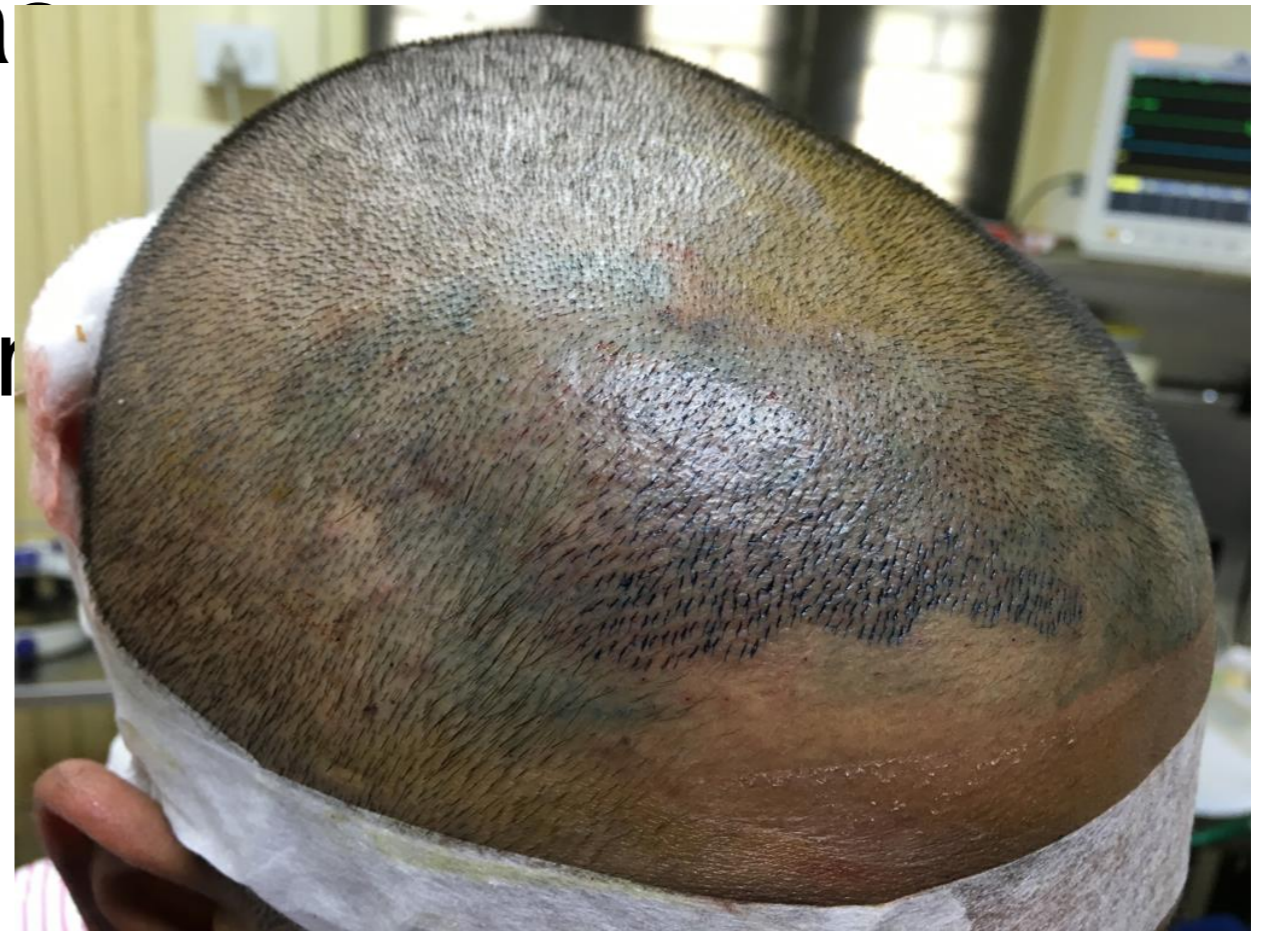Preperation of follicles

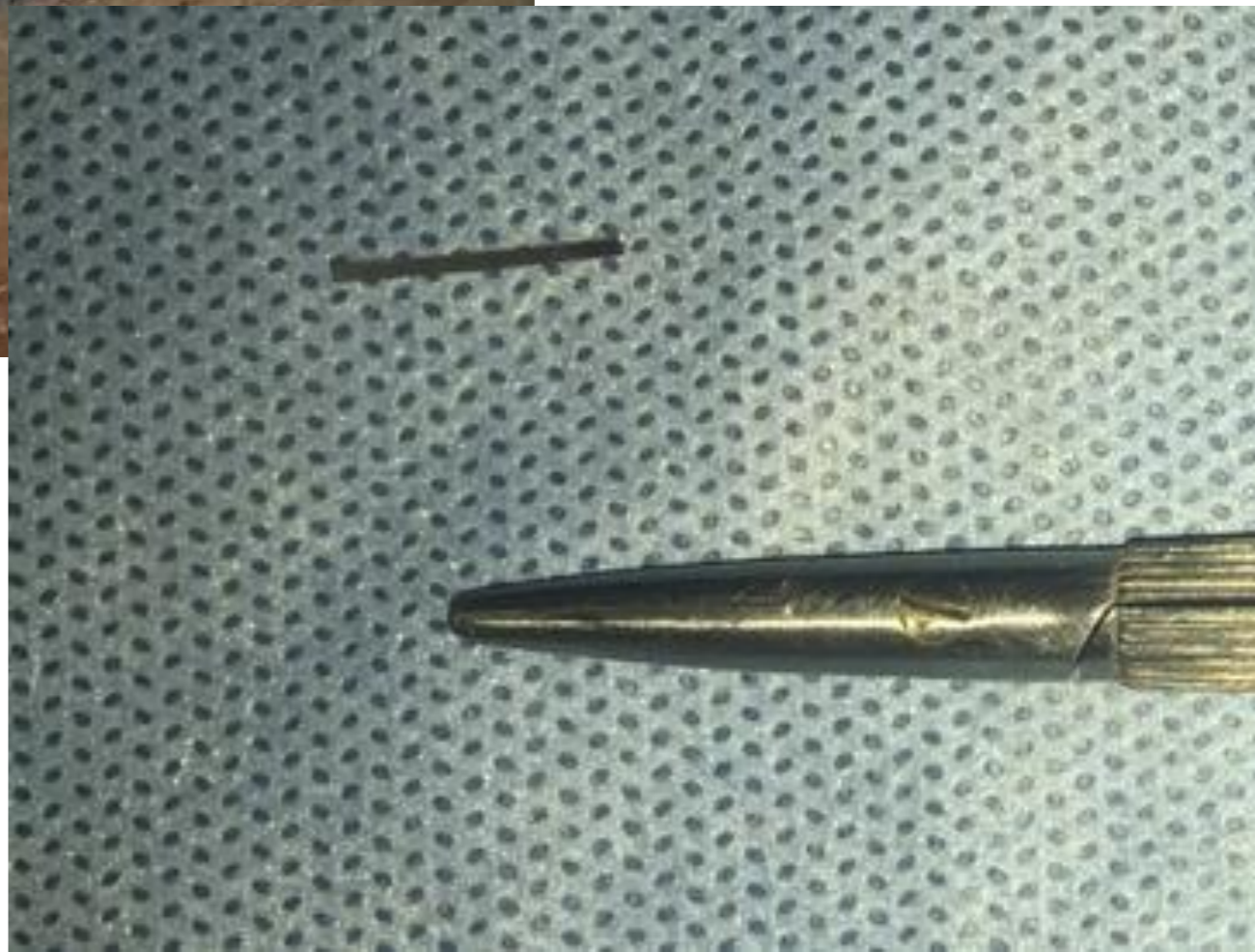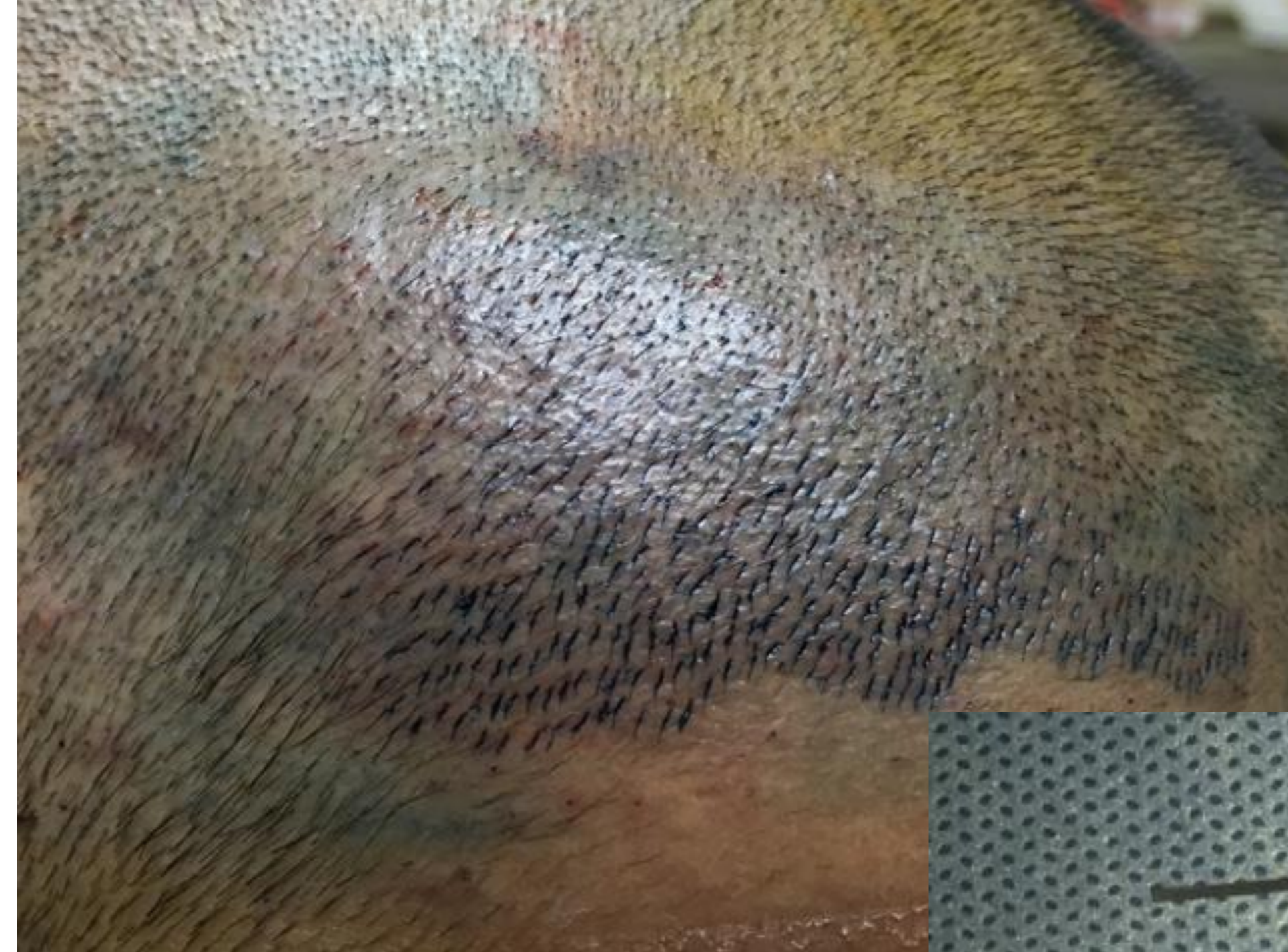- Time consuming
- Chilled Ringers lactate
- Sterility
- Seperate single, double, triple follicles

QuickTime™ and a
decompressor
are needed to see this picture.

Implantation

- Local anaesthesia applied before
- Tumescent with saline and adrenaline
- Pre hole with slits
- Implanters





Implantation

- Hairline - single hair, irregularly irregular
- Increase density as you go backwards for about 2cms
- Decrease density beyond to cover a larger area

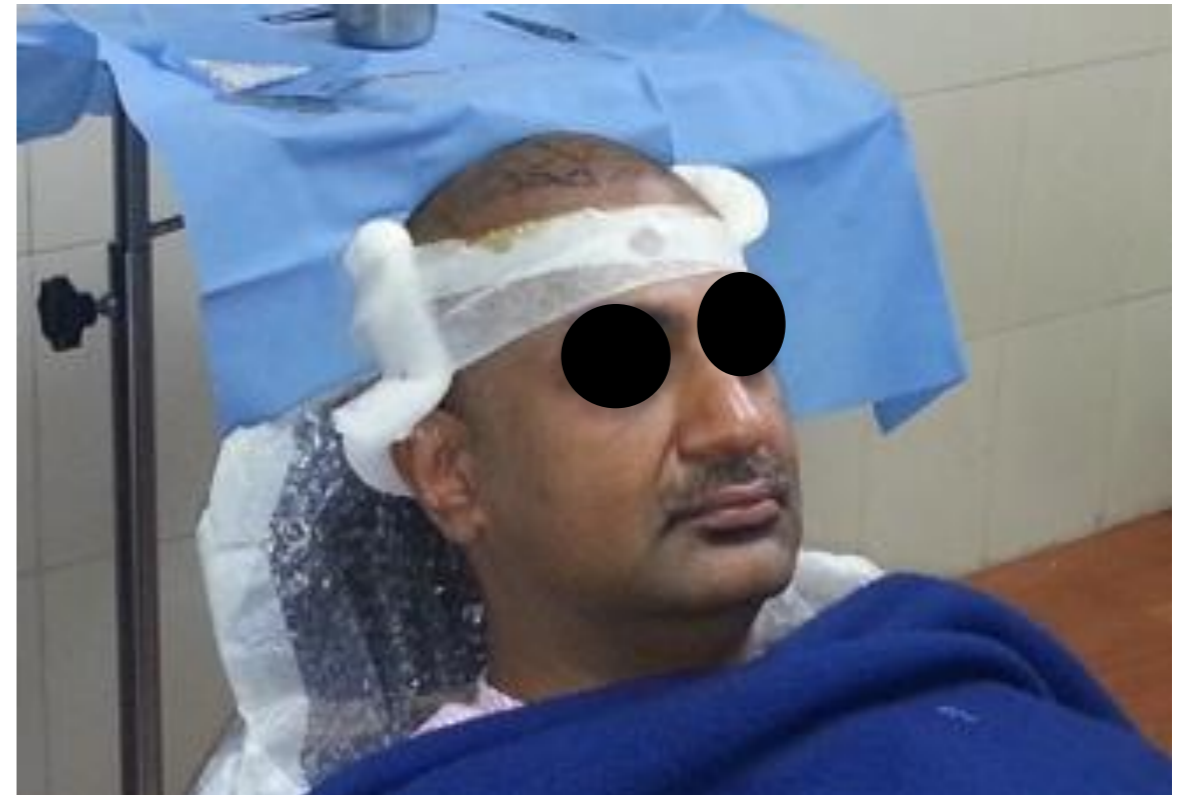Implantation - Direction

- Frontal hairline - Acute
- Less acute as you go backwards
- Temporal region inferior

QuickTime™ and a
decompressor
are needed to see this picture.

Post op

- Tight dressing to the donor area
- Recipient area kept open
- Regular dabbing with saline gauze at home
- Analgesics and Antibiotics



Post op care

- Remove dressing at 48 hrs
- Allow to shampoo donor site after 48 hrs
- Allow to shampoo recipient after 5 days
- Oil application on donor area

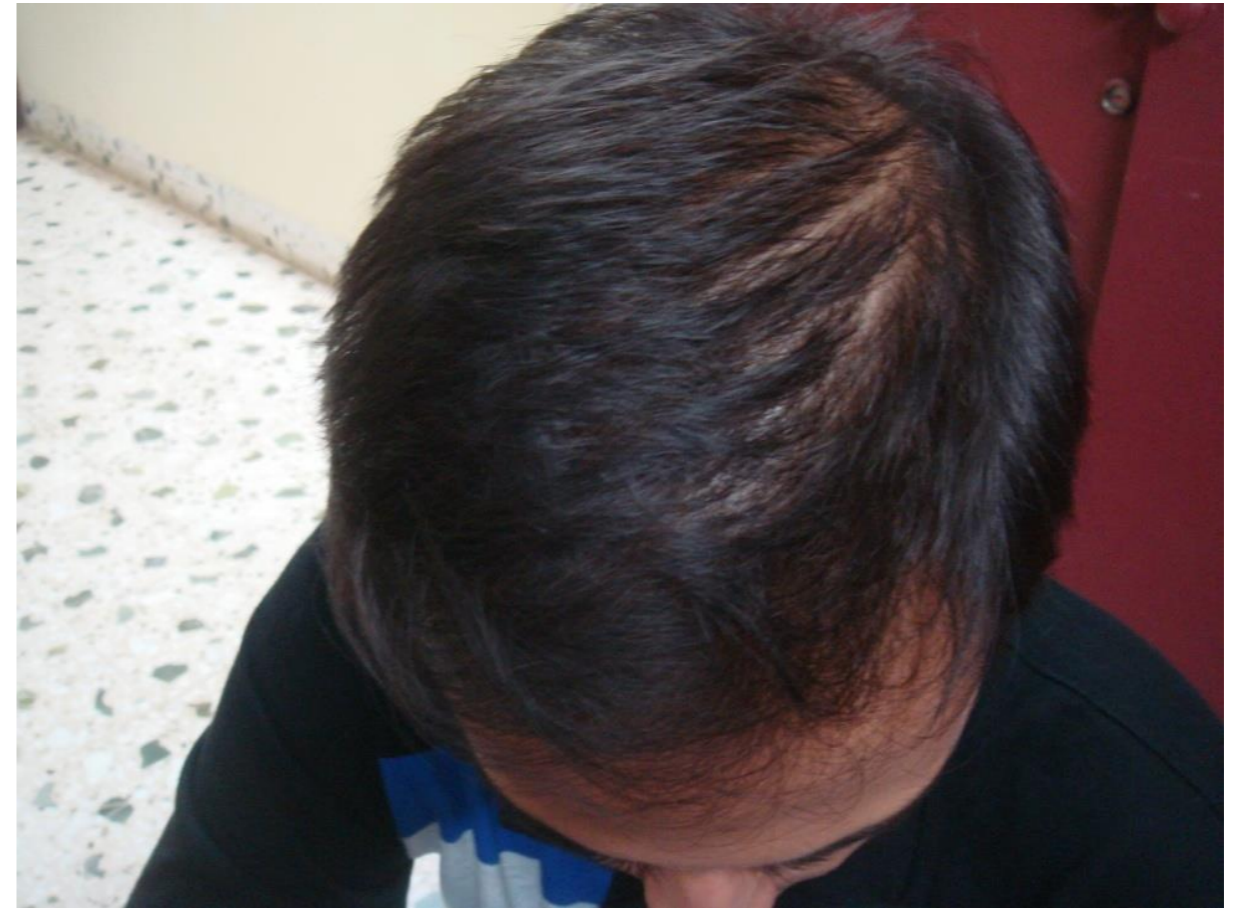
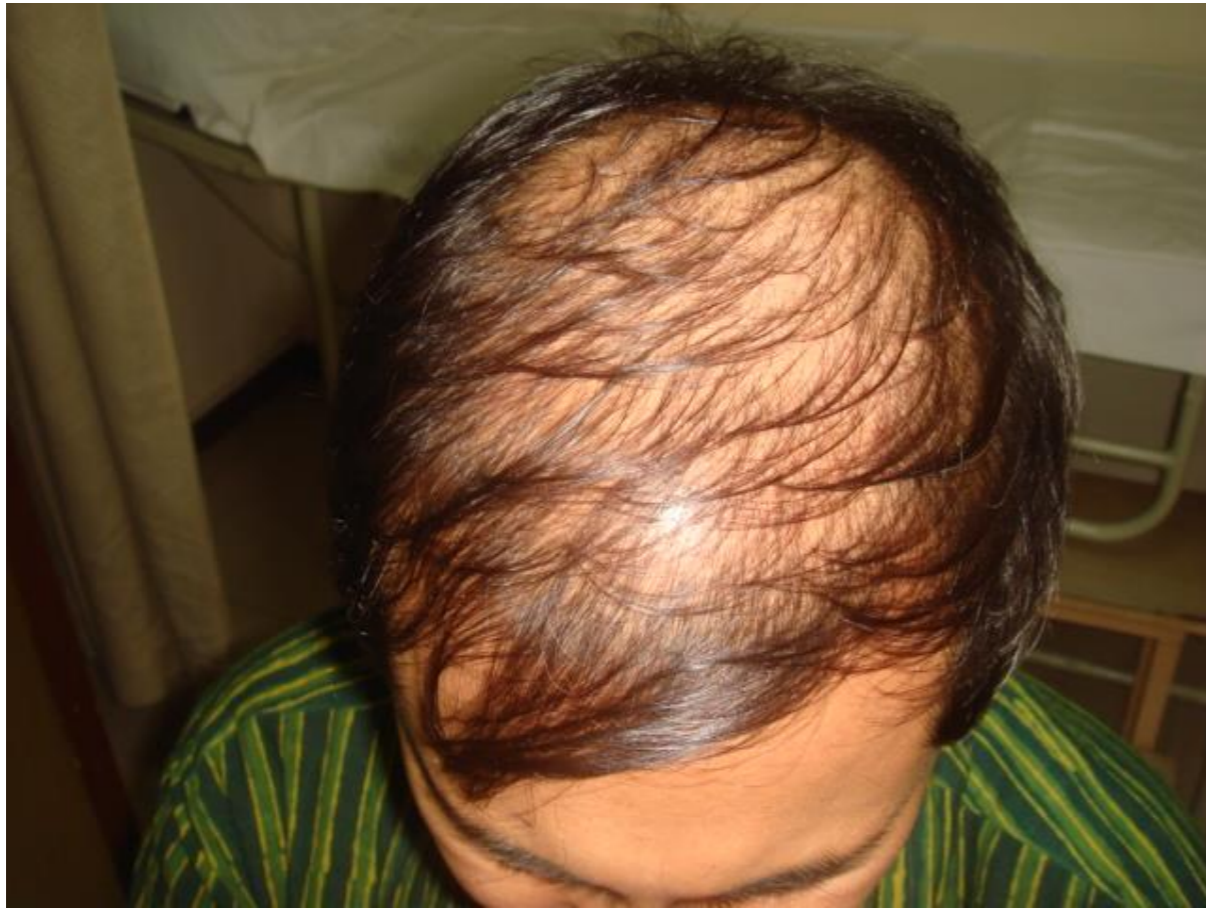
Post op care

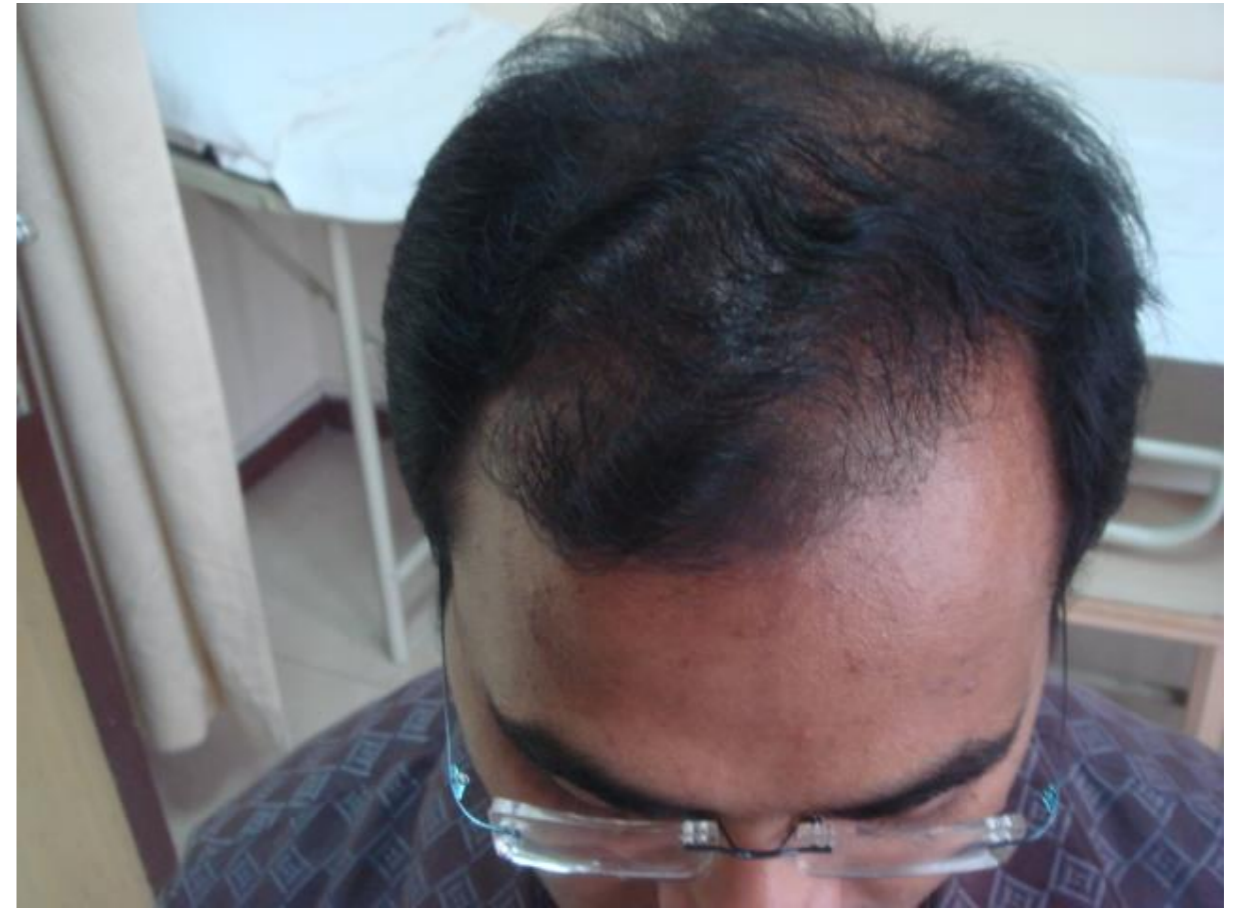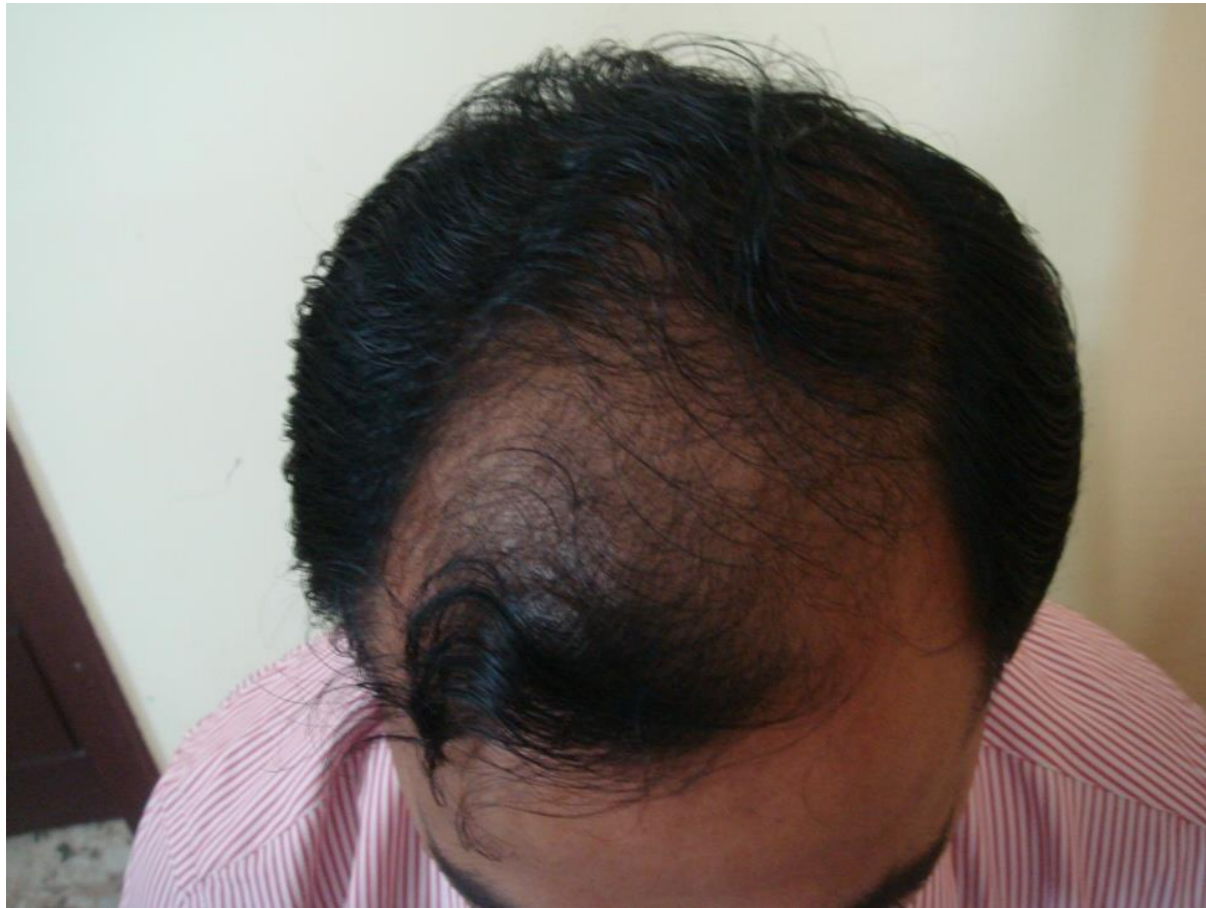- Start on medical treatment for 9 - 12 months
- Minoxidil
- Finasteride
- Hair oil



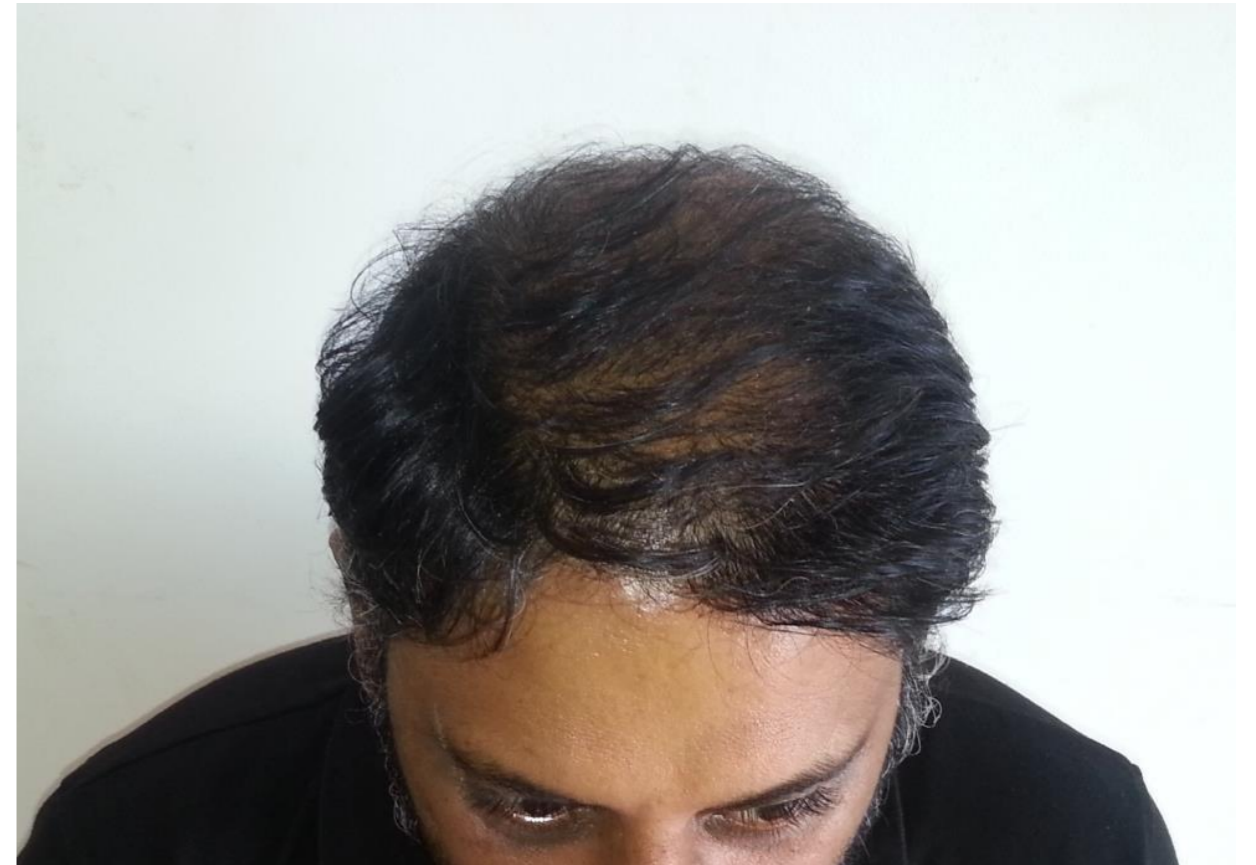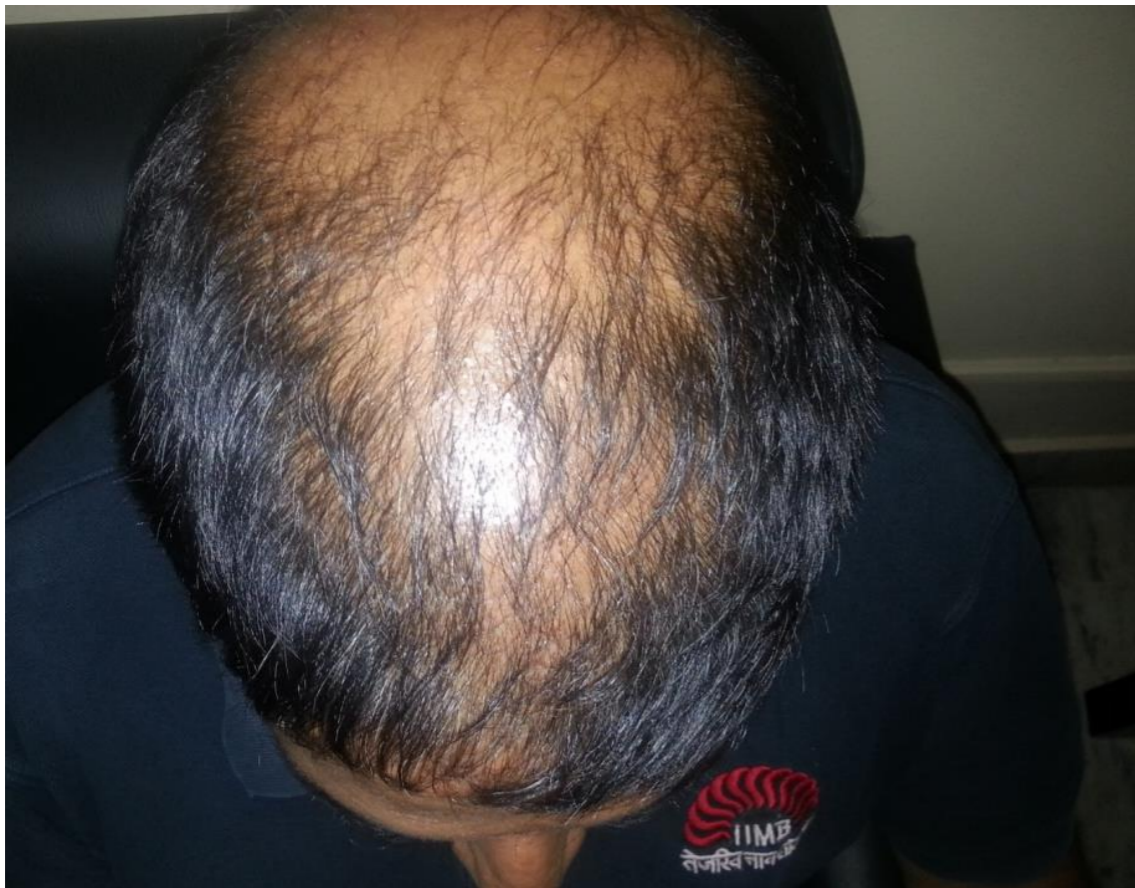Results - Medical



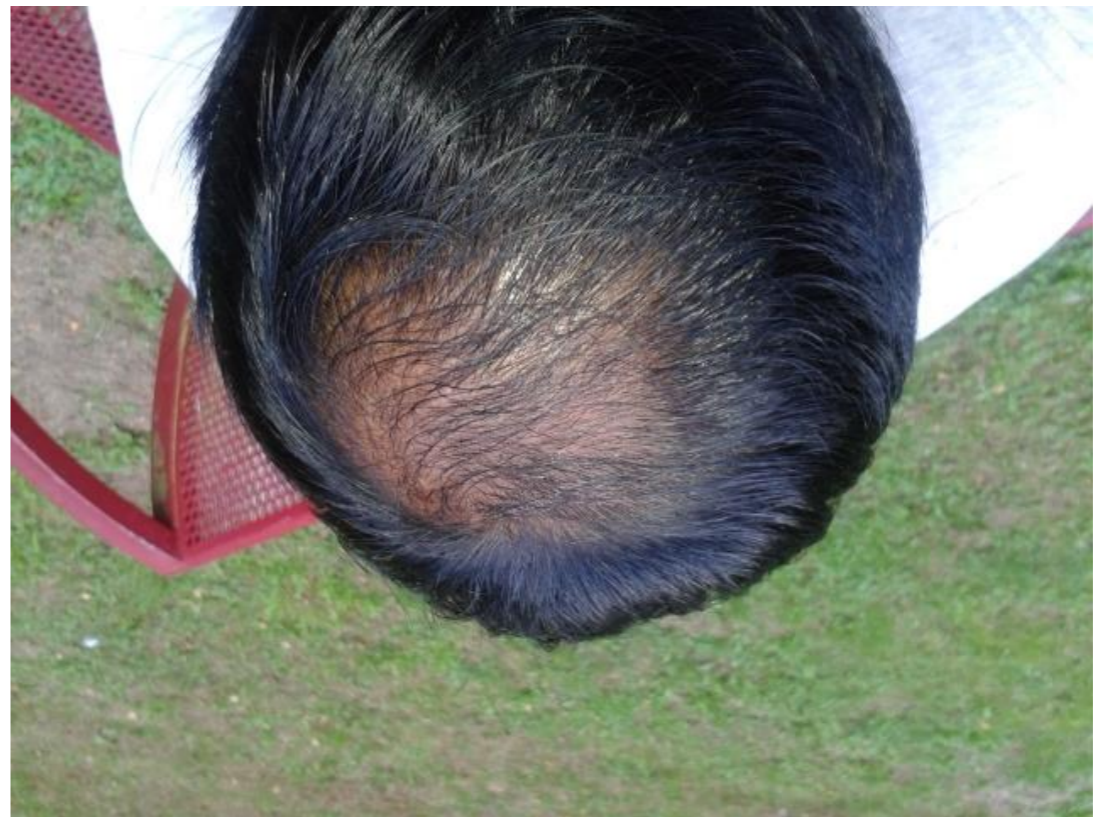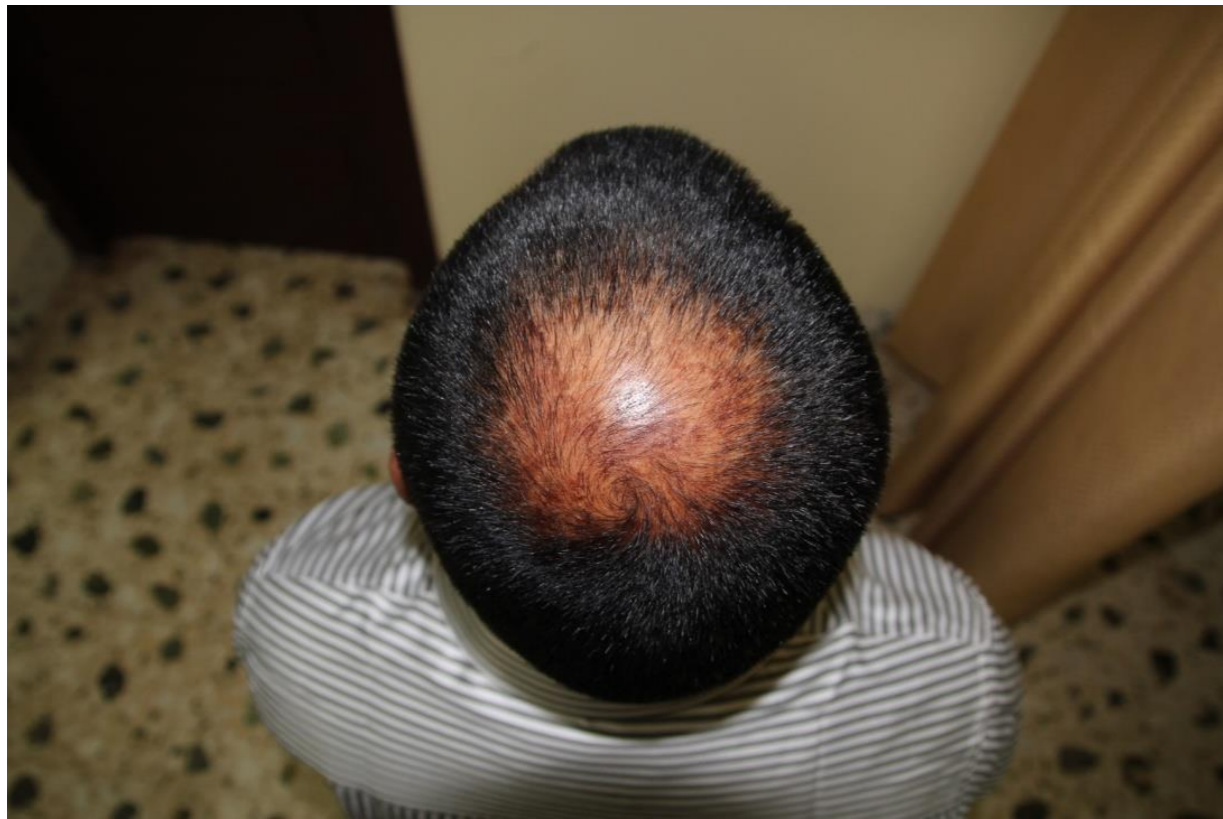Results - Medical



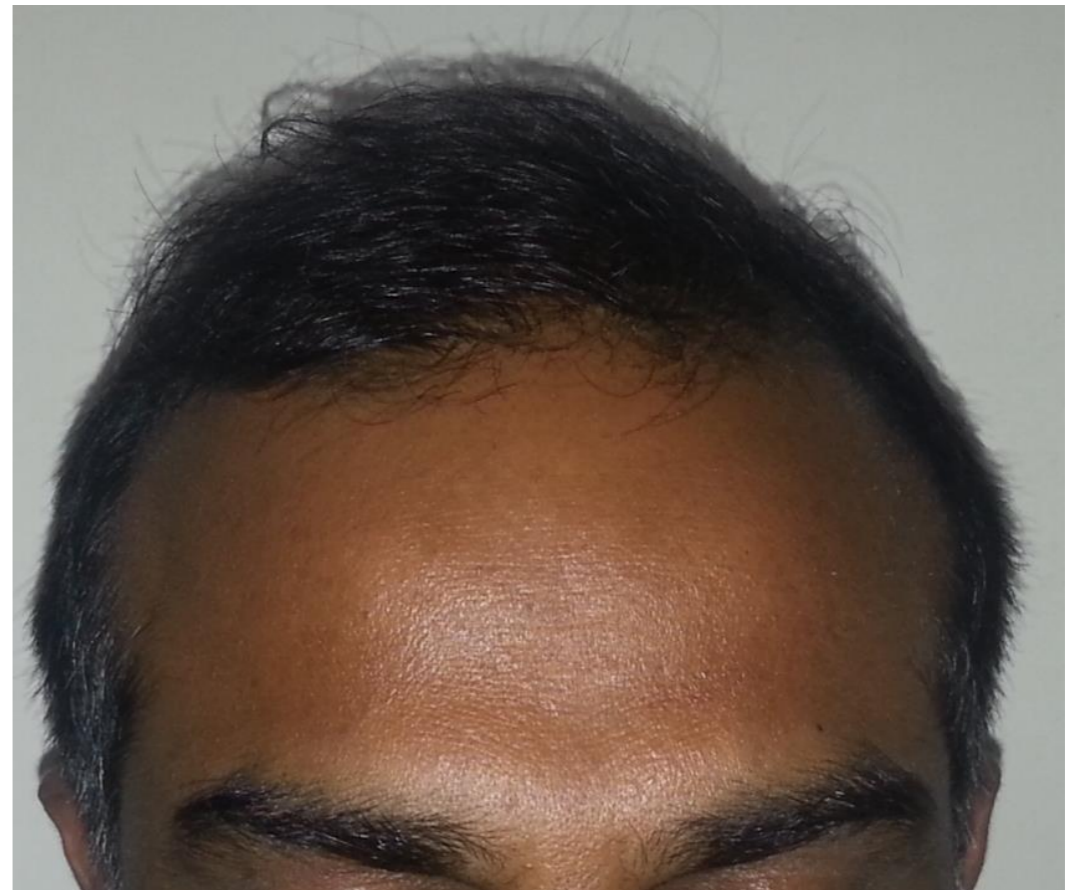
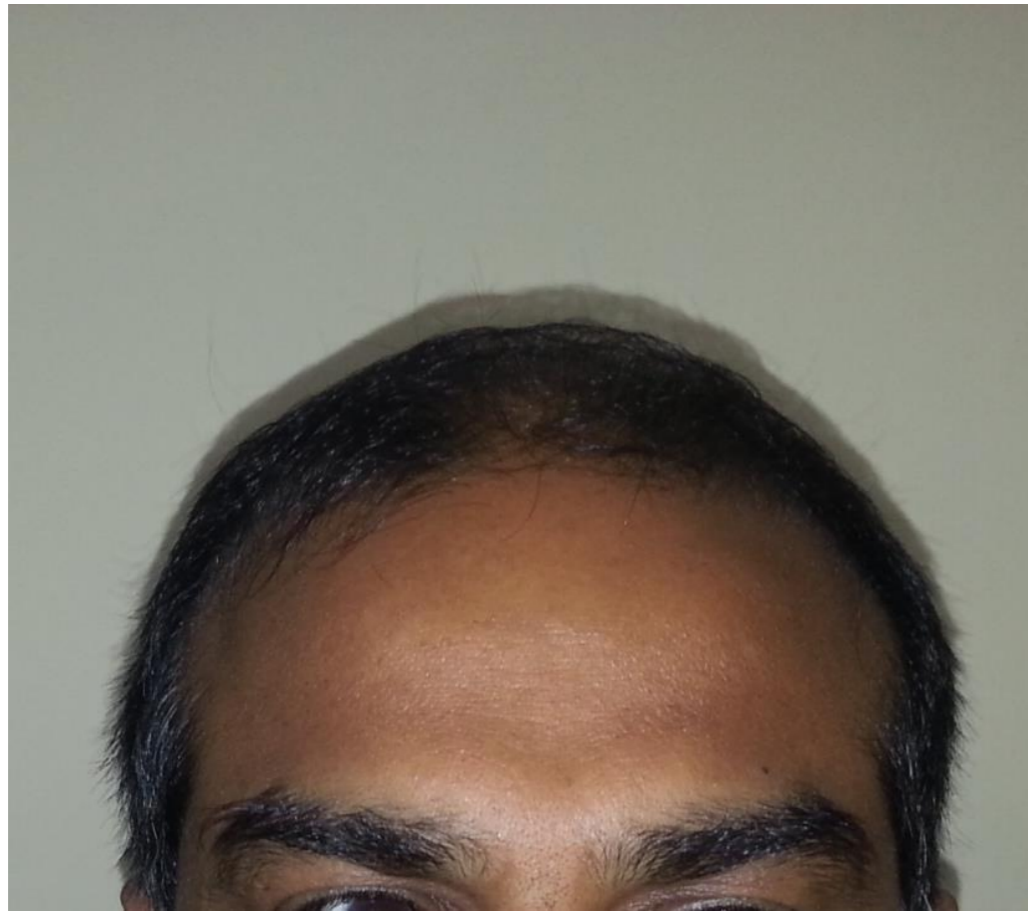Results - Surgical



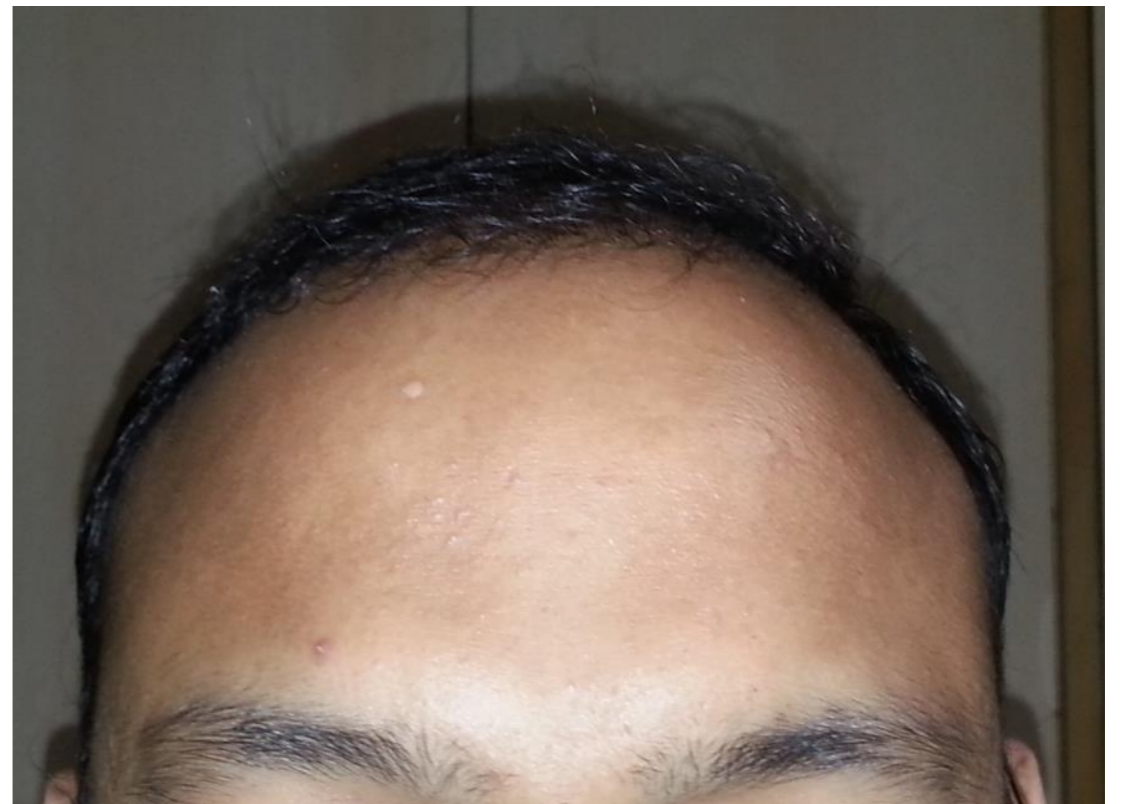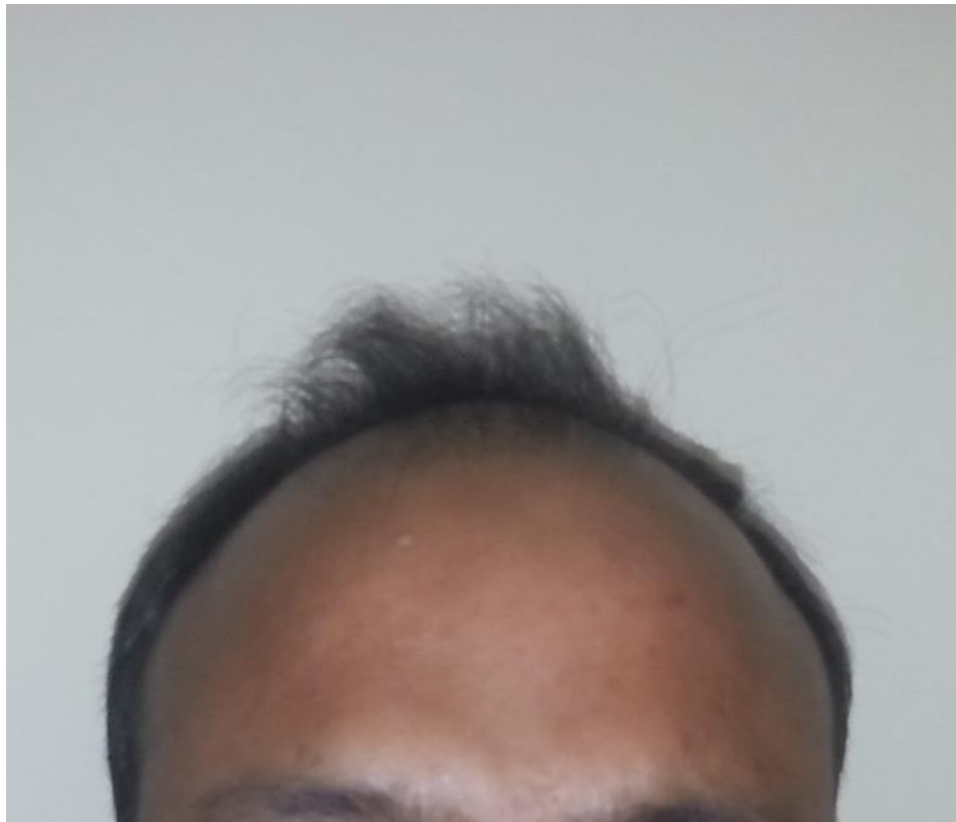Results - Surgical



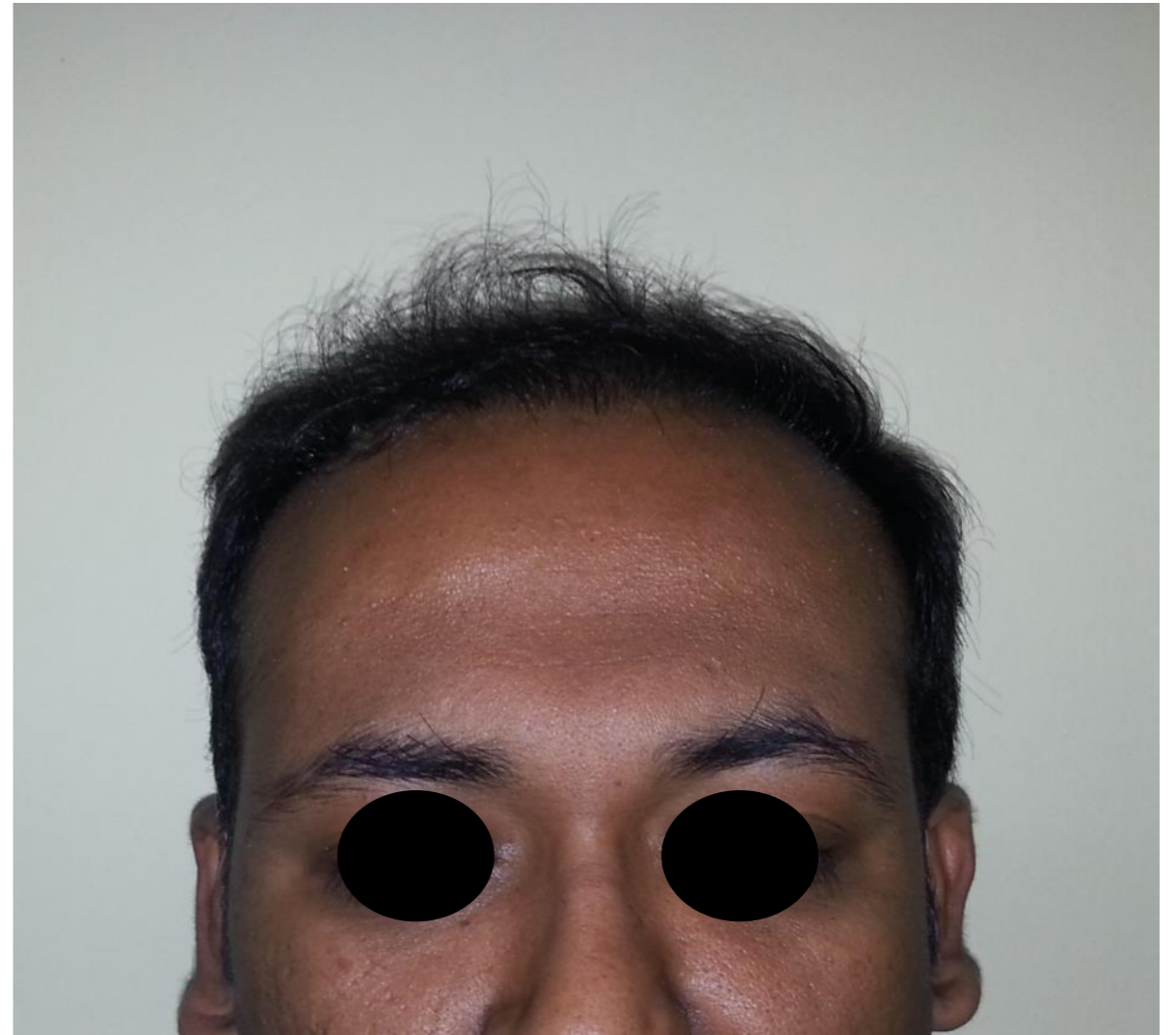Results - Surgical



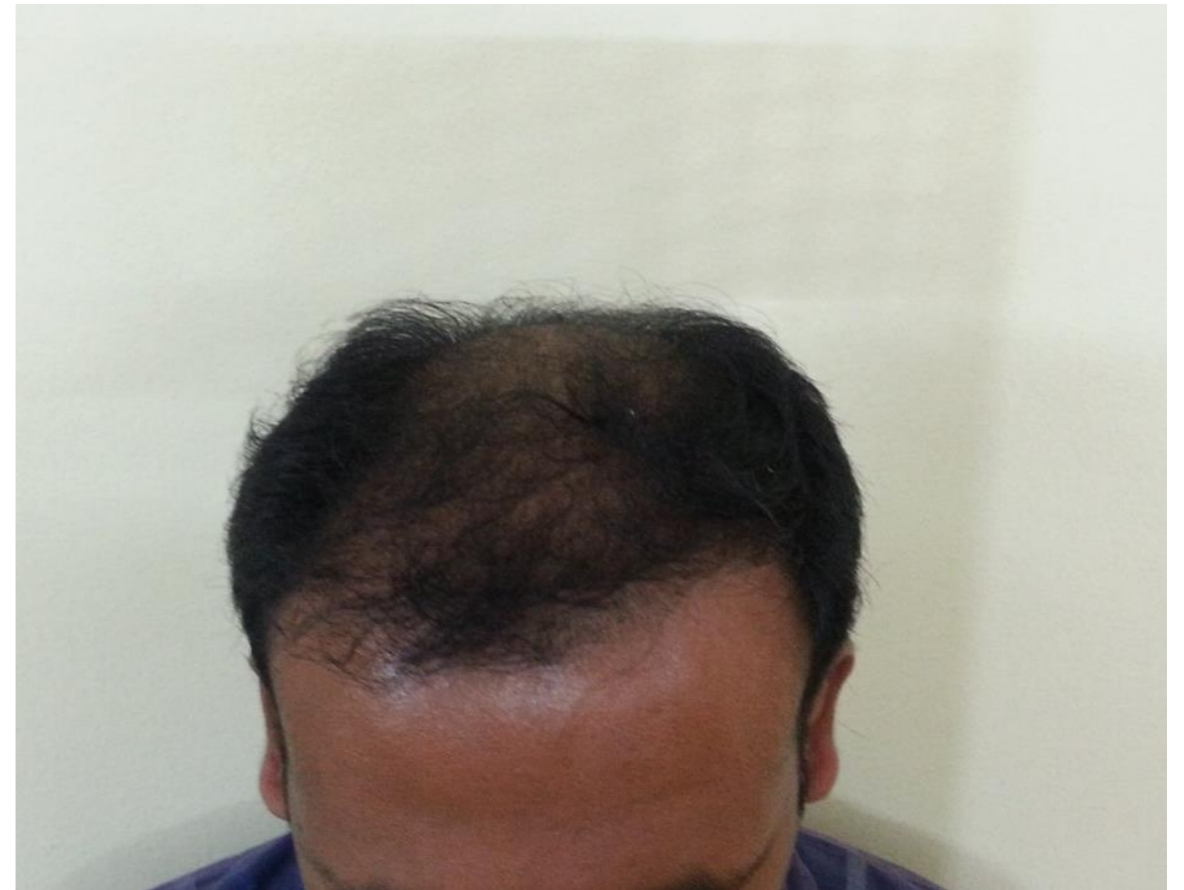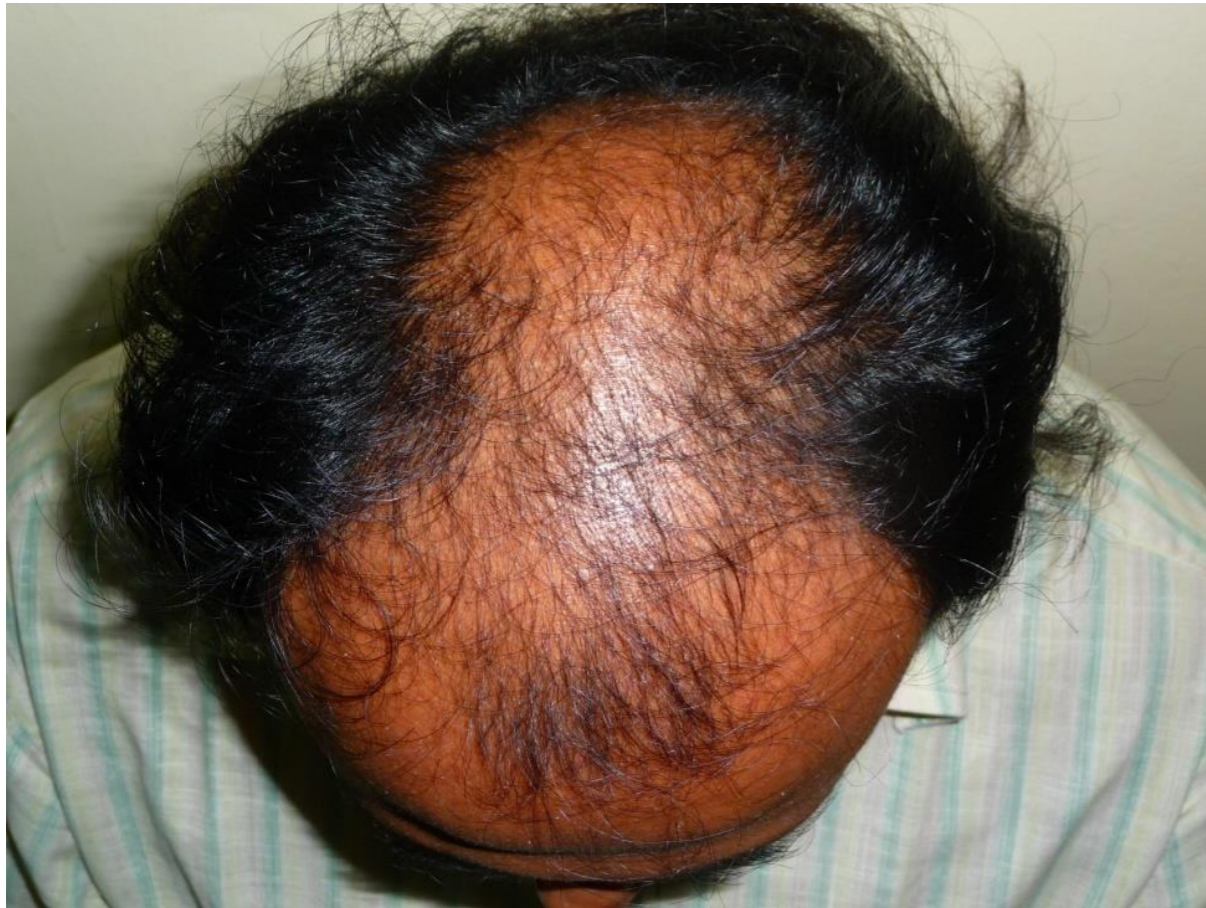Results - Surgical



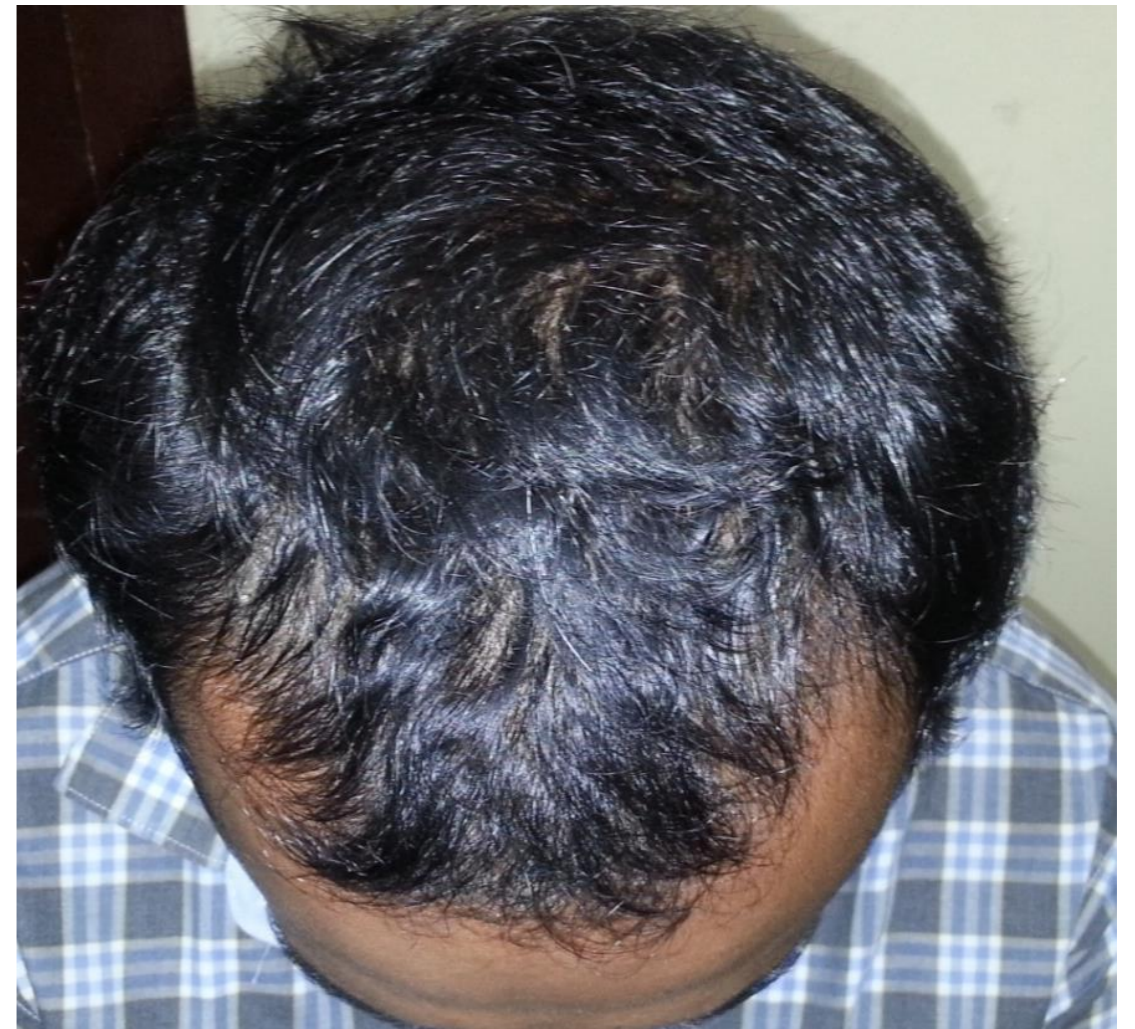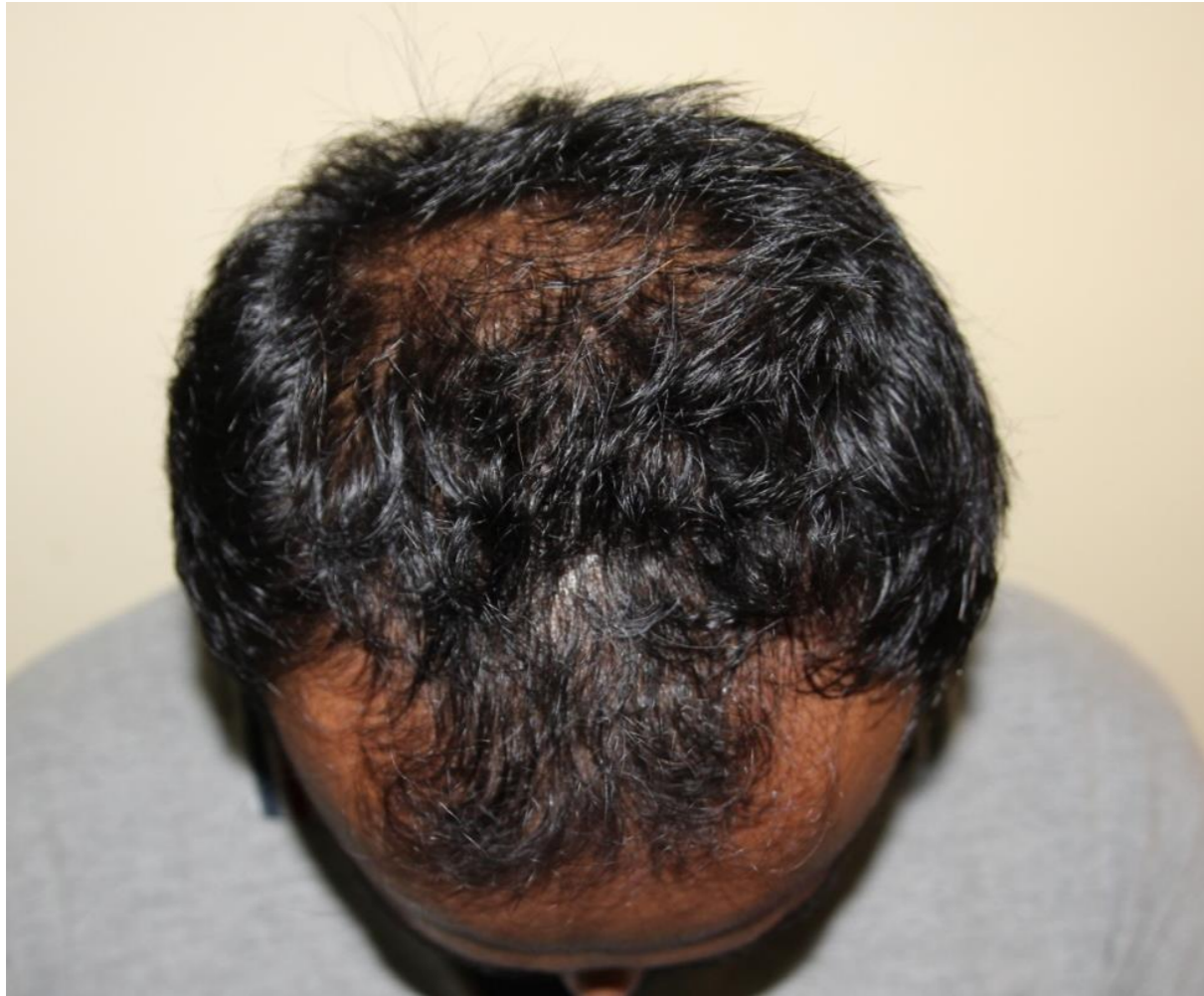Results - Surgical



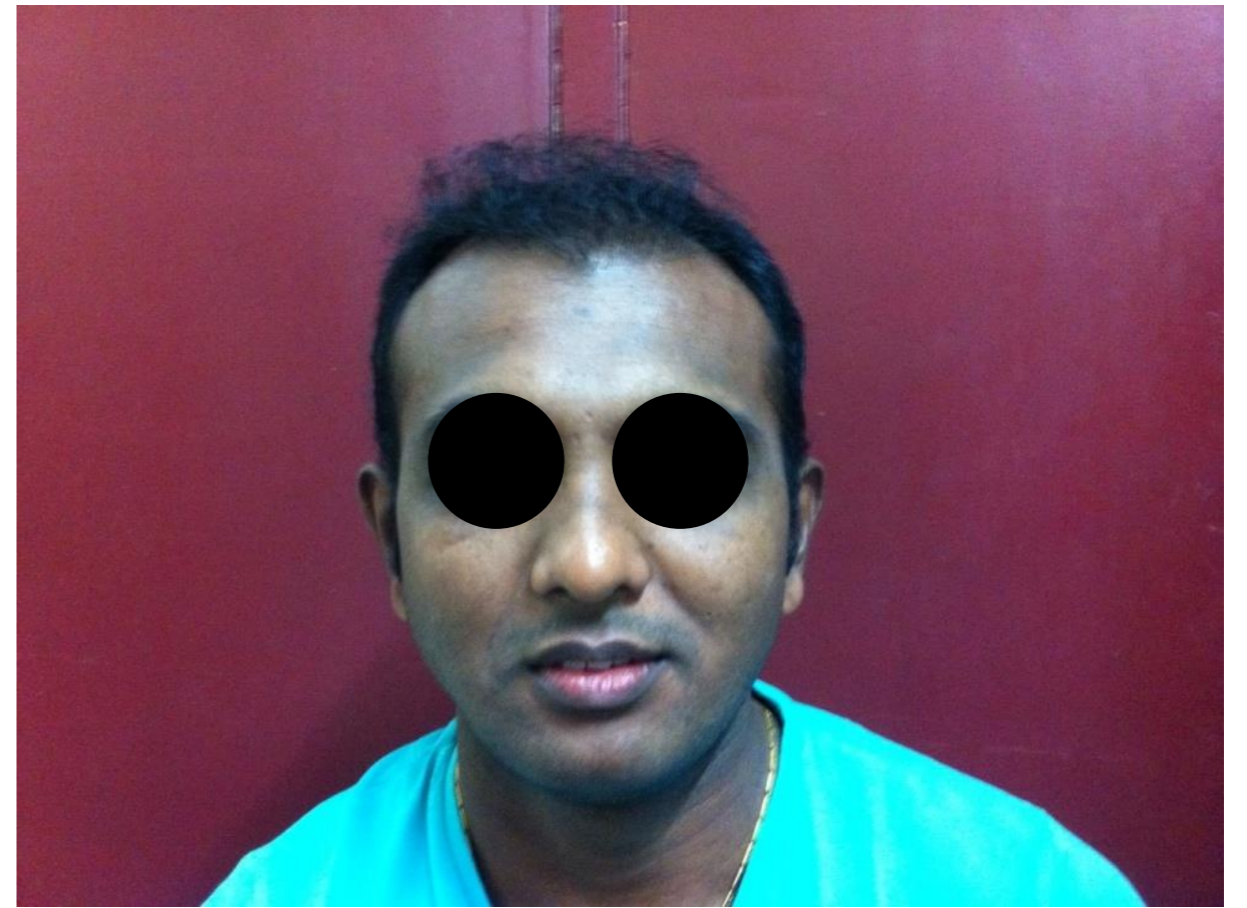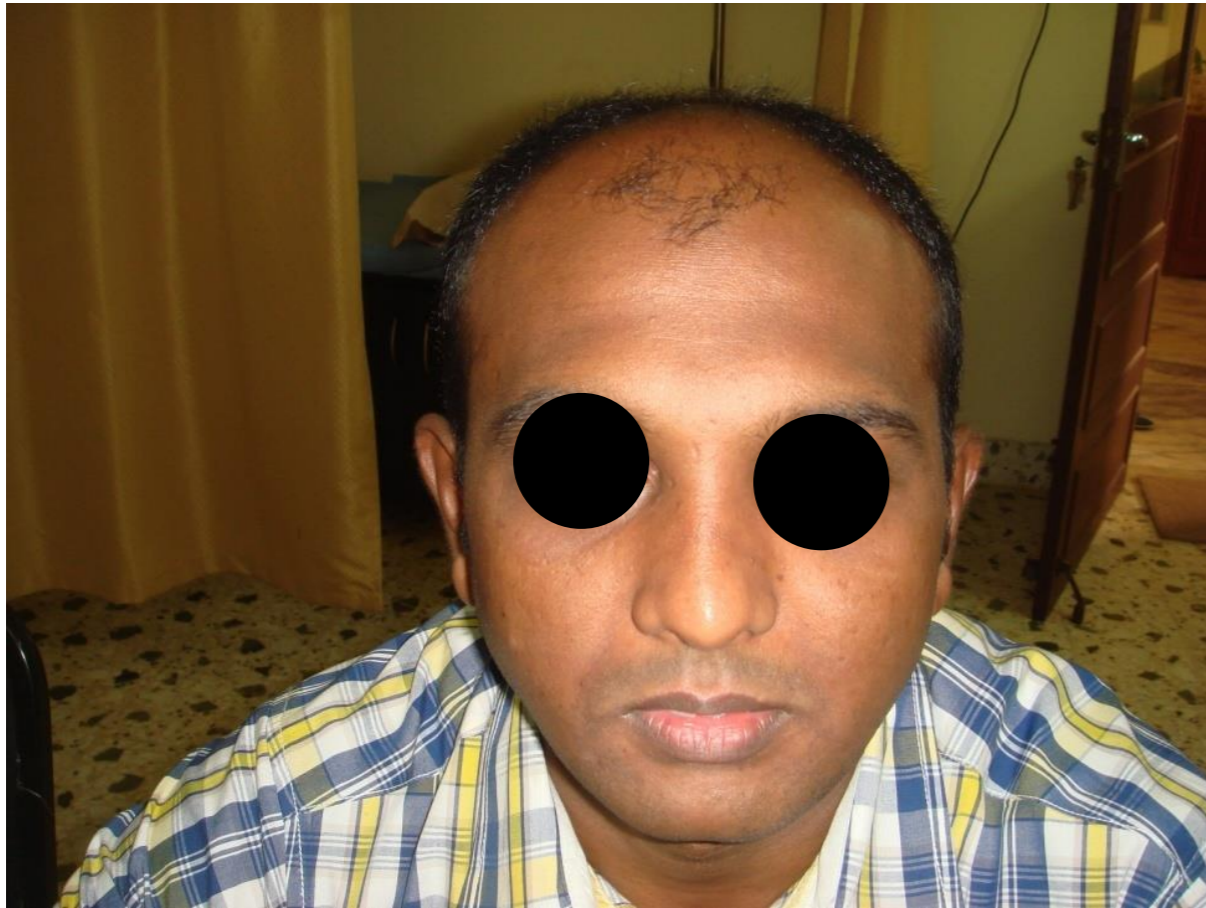Results - Surgical



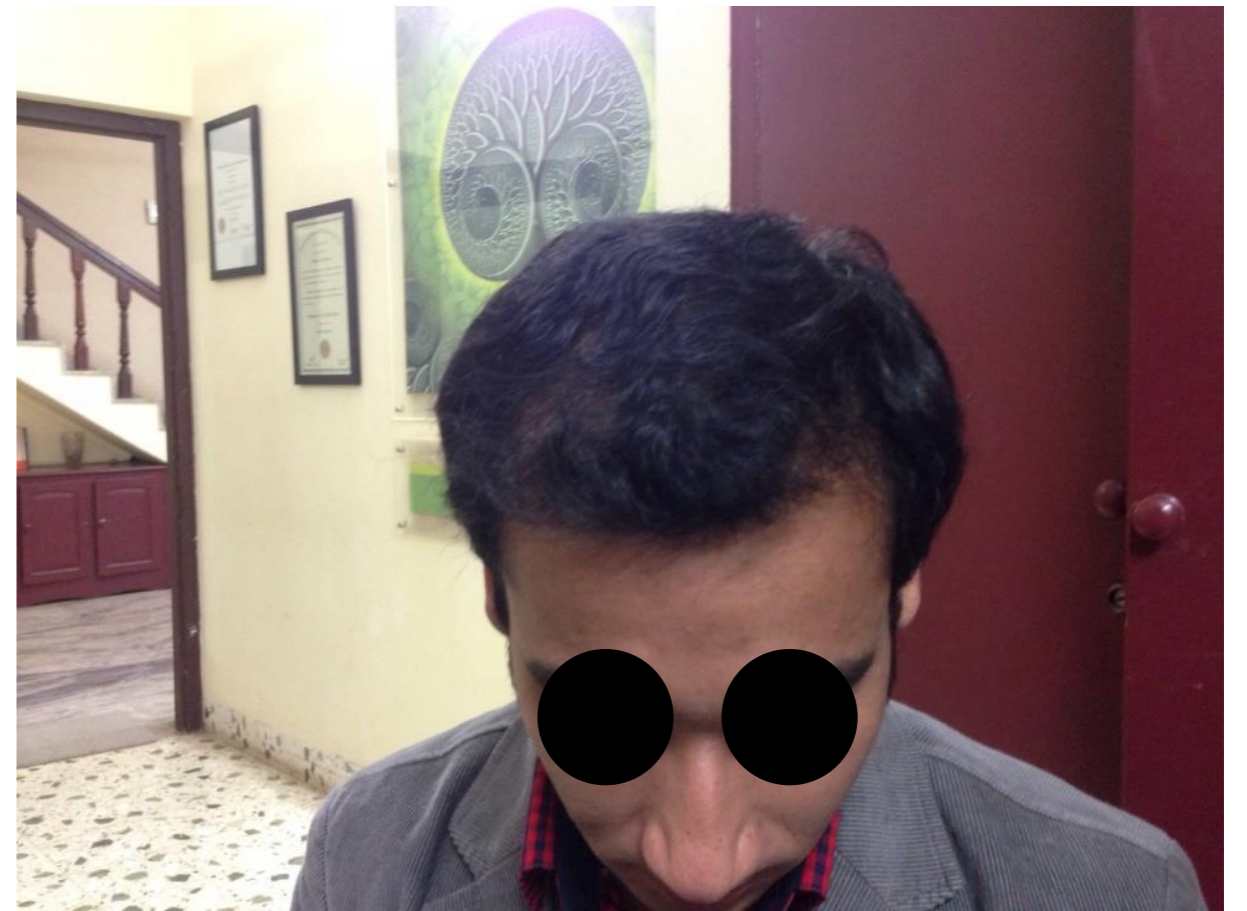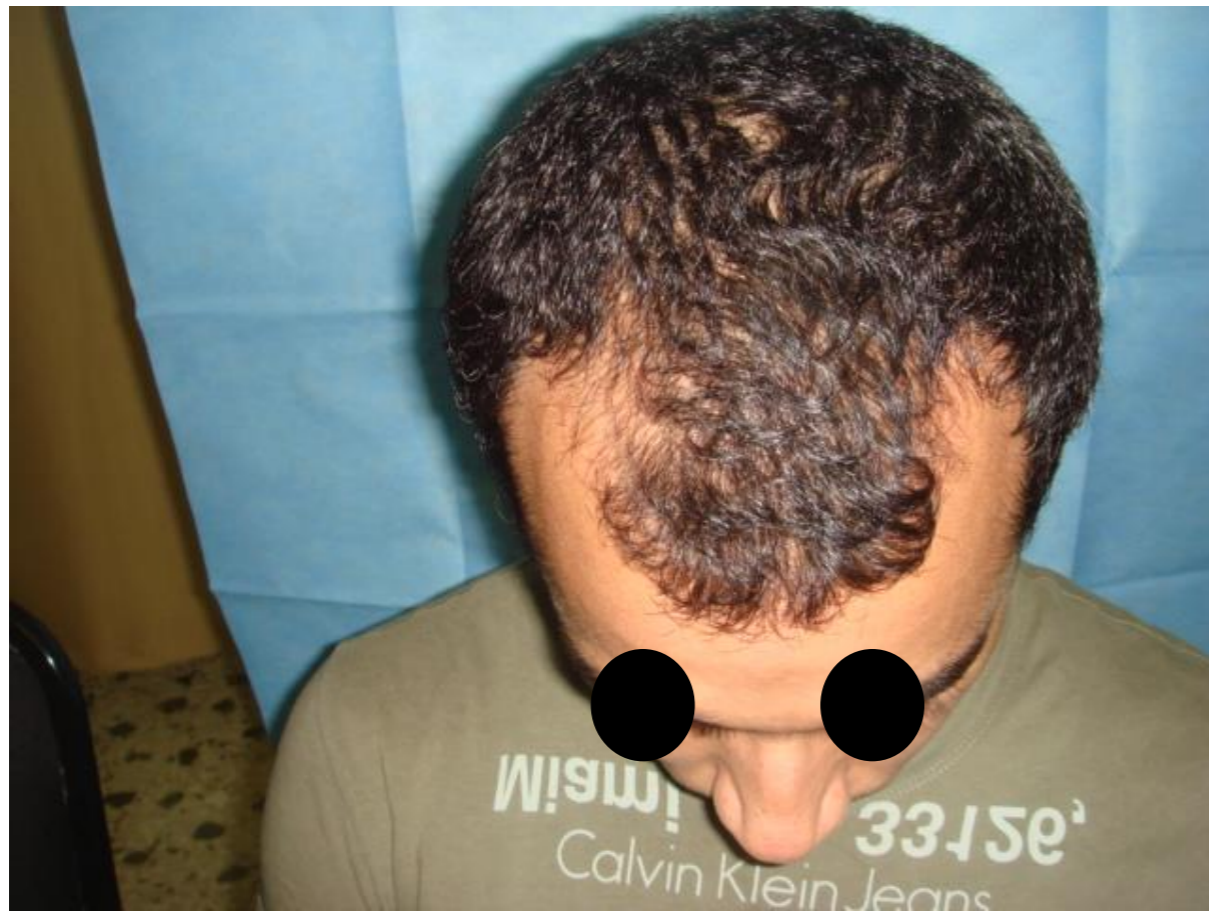Results - Surgical



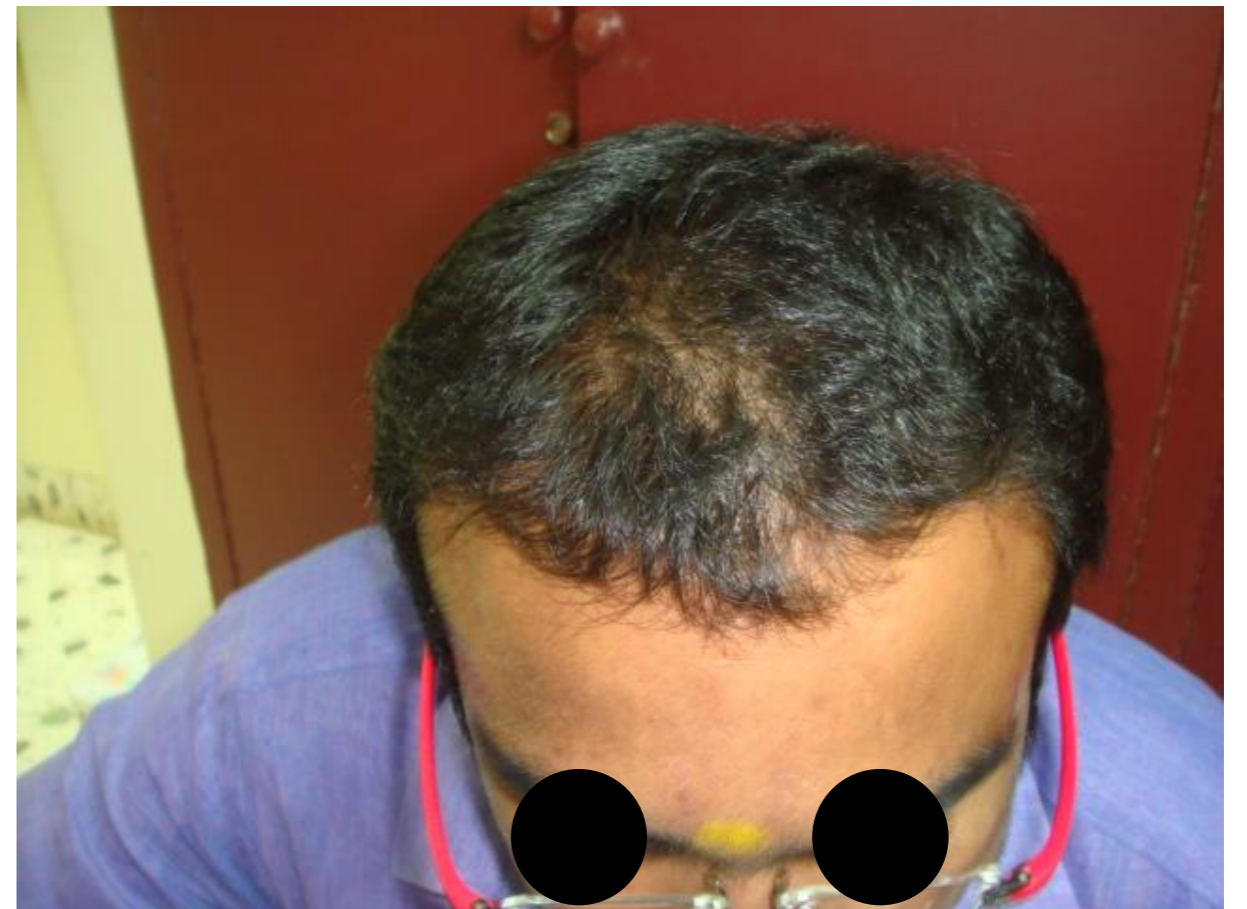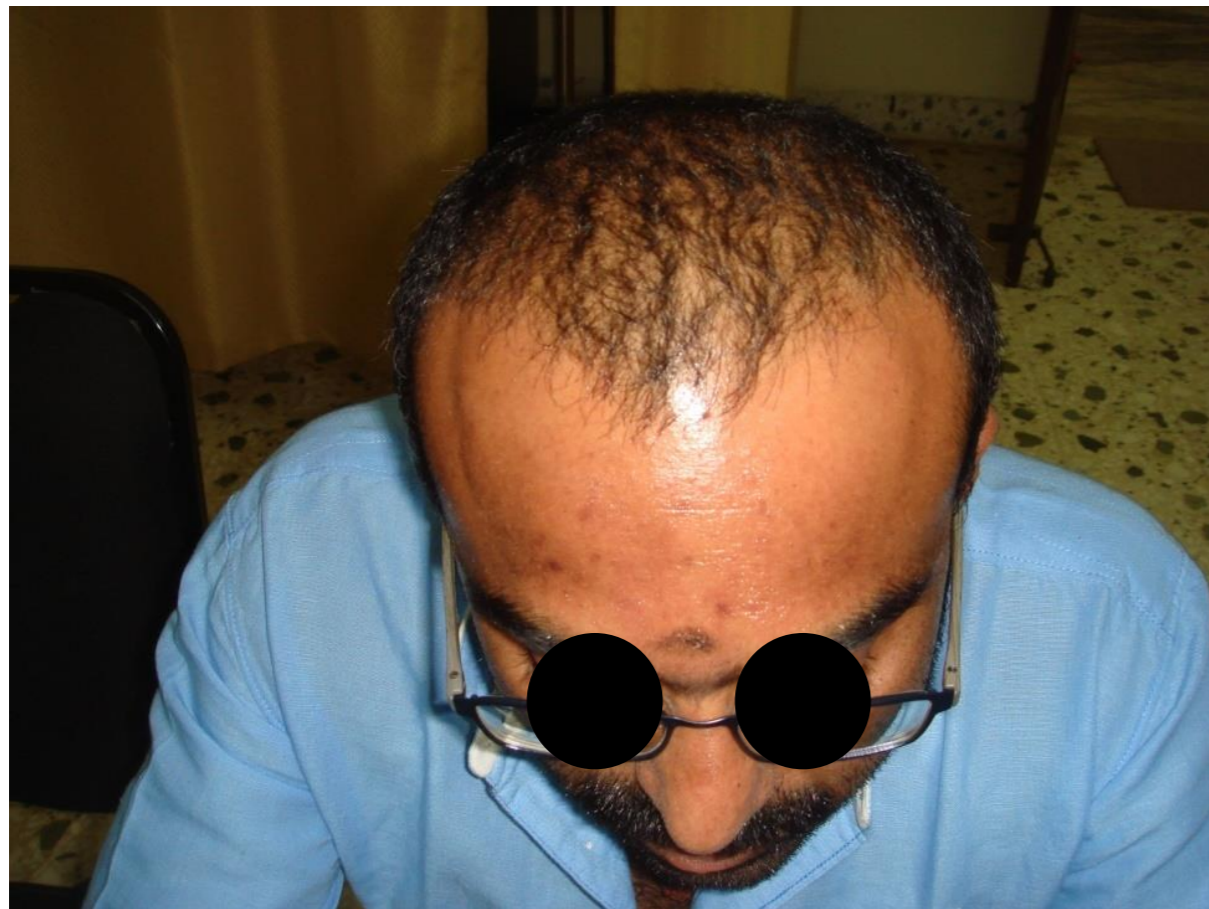Results - Surgical



Results - Surgical



Results - Surgical



A Clinique Belle presentation