

McIndoe's Vaginoplasty for Vaginal Agenesis - MRKH Syndrome

Dr. Srikanth V

MBBS; MS; FRCS(edin); FRCS(Glasg); MCh;
DNB (Plastic Surgery)

Plastic Reconstructive & Cosmetic Surgeon

Clinique Belle

MRKH Syndrome

- Mayer-Rokitansky-Kustner-Hauser Syndrome
- Underdevelopment of Vagina and Uterus
- Normal ovaries
- Type 1- Isolated reproductive organ maldevelopment
- Type 2 - Associated with kidney, spinal, ear or heart defects

- What is Vaginoplasty ?
- Reconstruction of the
Vagina

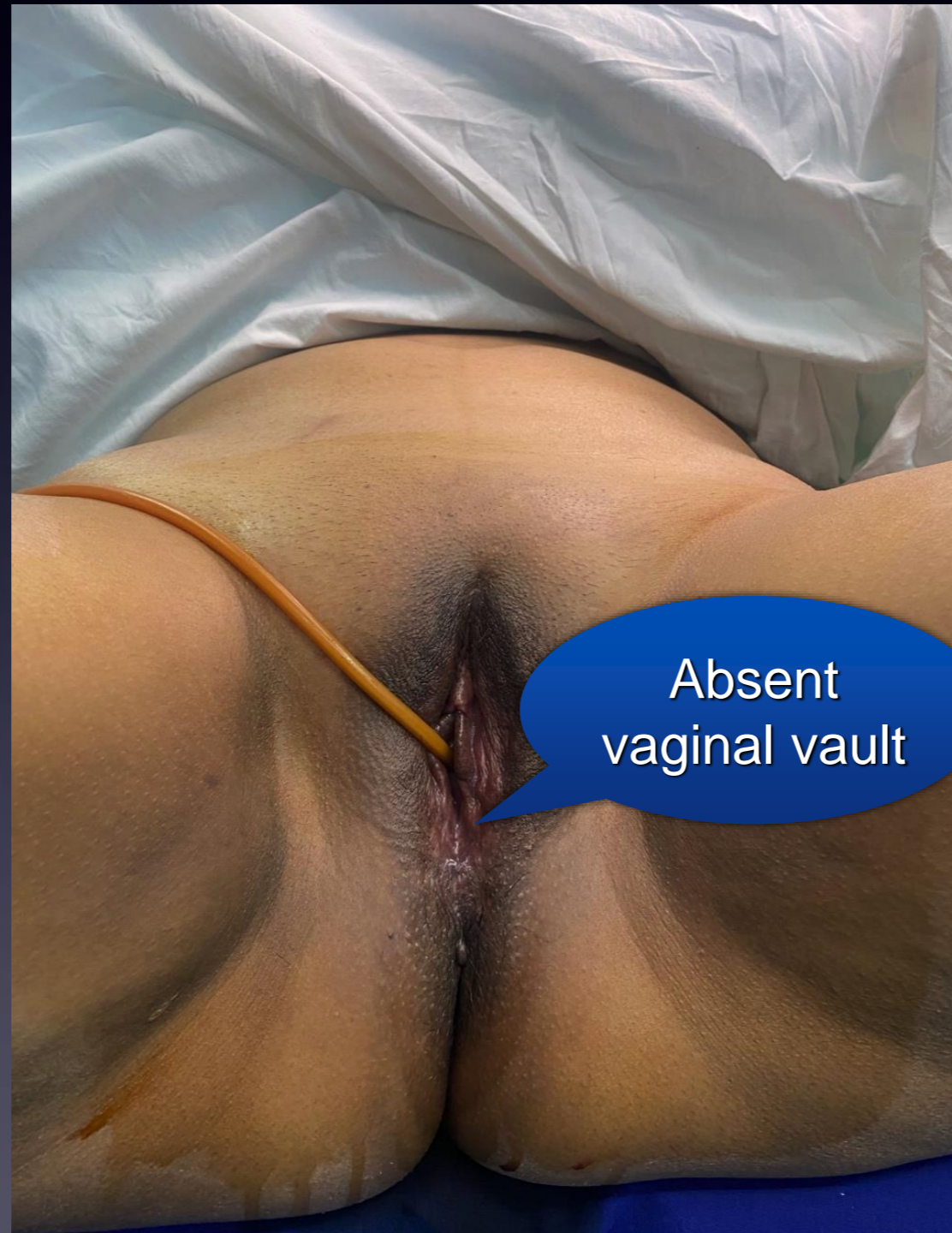
How is it treated - McIndoe procedure

- A new vaginal space is created between the bladder and the rectum
- The new space is lined with a skin graft taken from the thigh

Post operative care

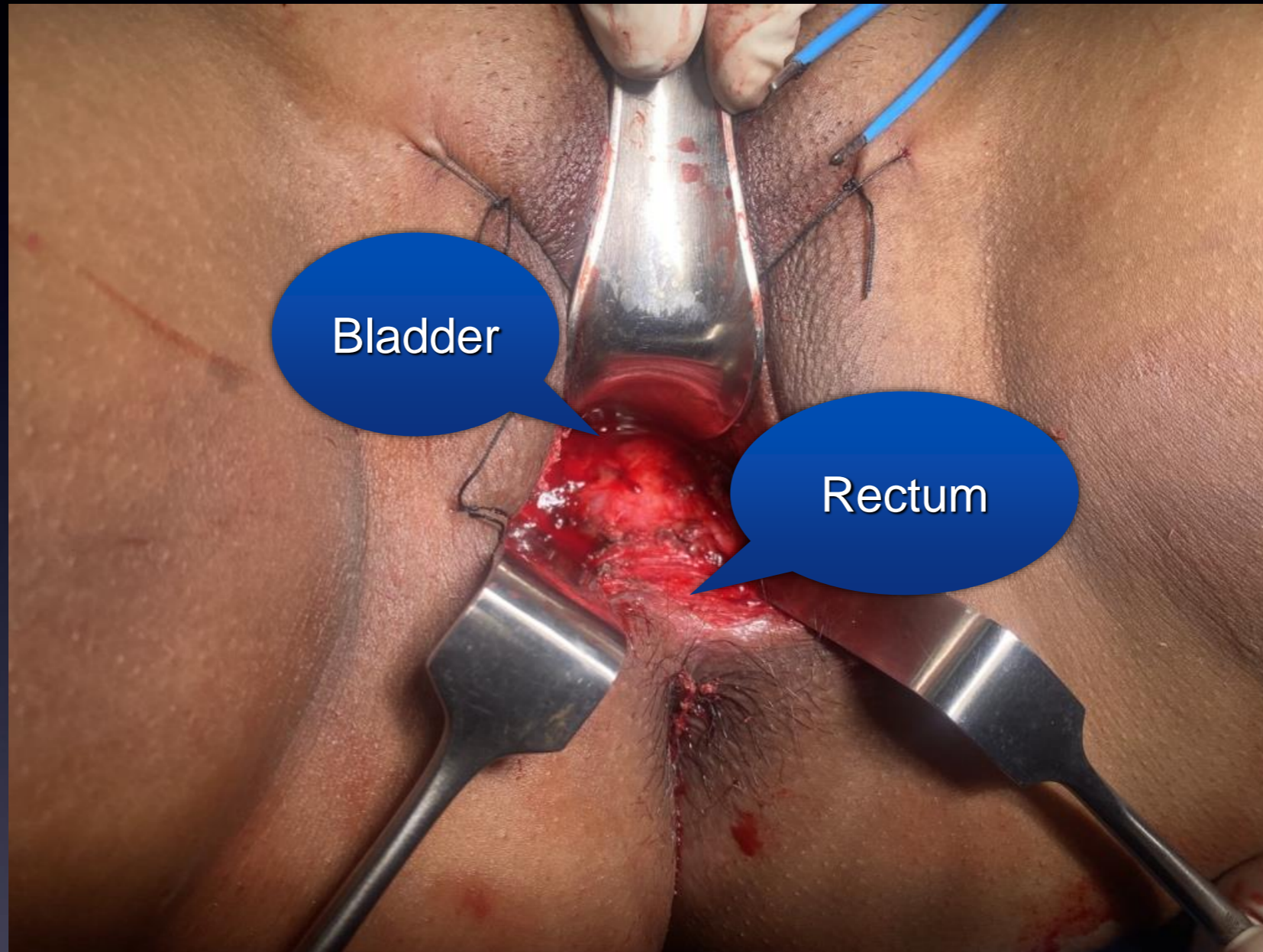
- A special mould is used till the skin graft settles down
- Dilators need to be used till regular sexual activity is practised

Absent Vaginal vault

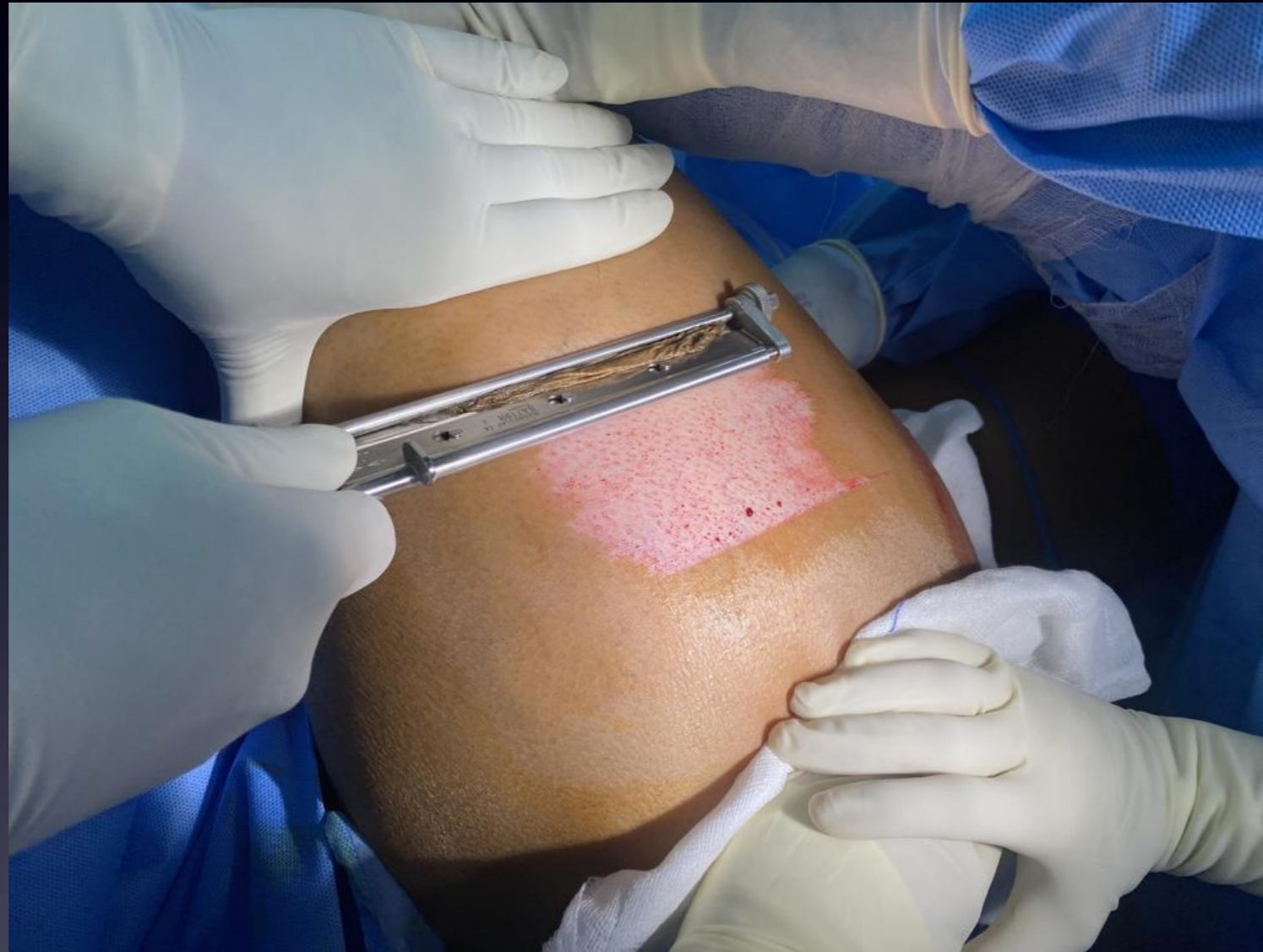

Absent
vaginal vault

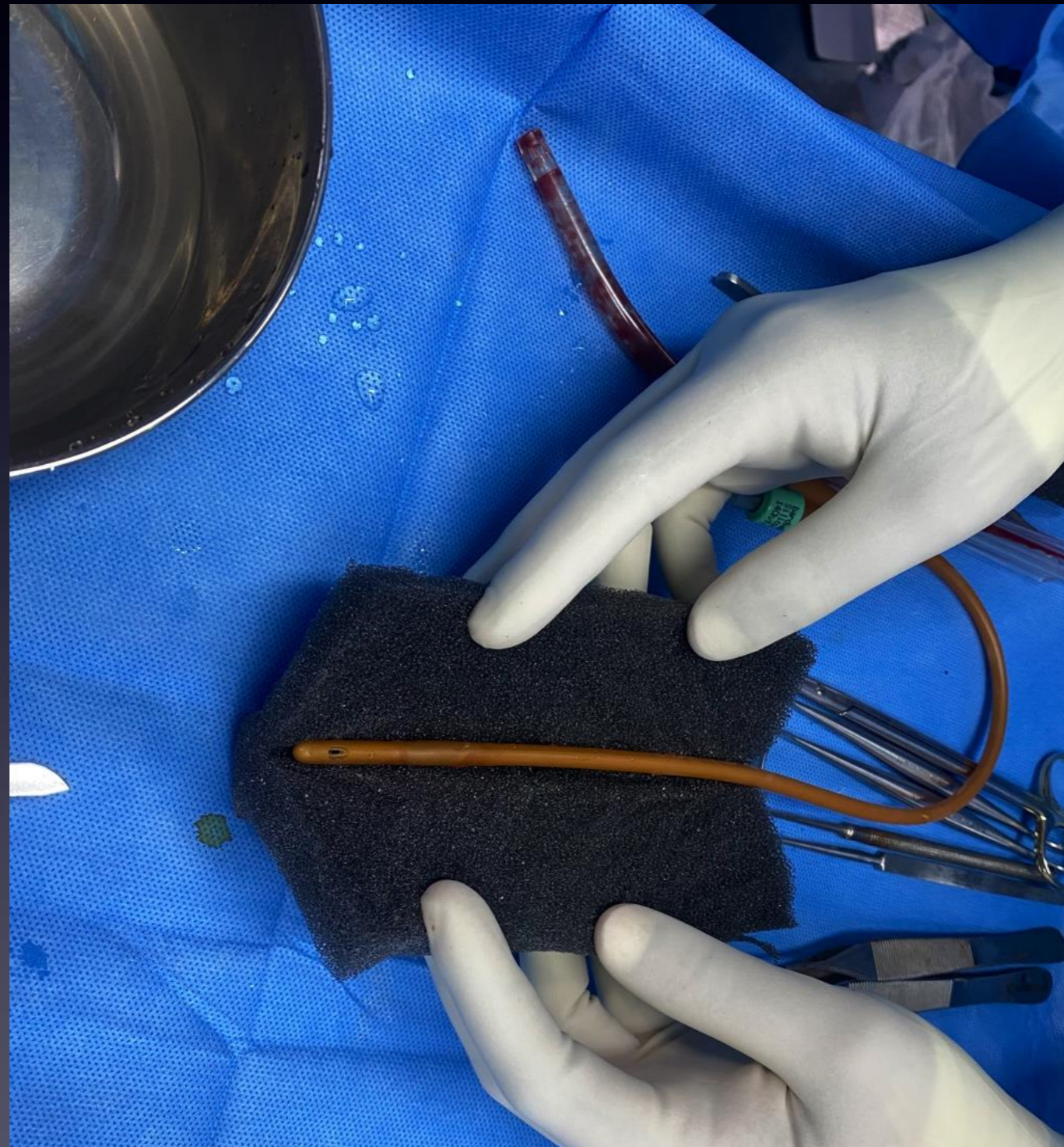New vaginal vault space created between bladder and rectum



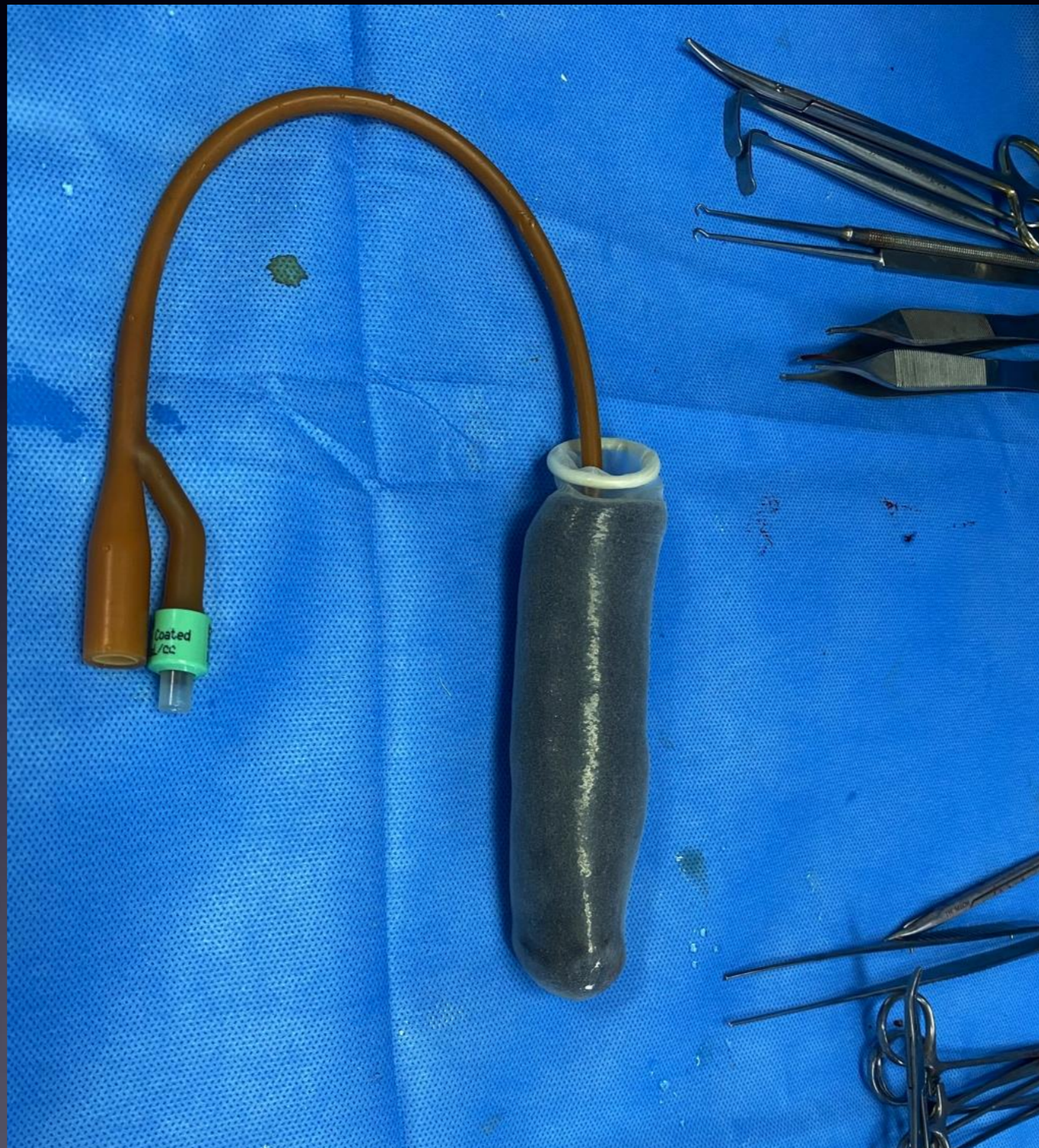Split skin graft being harvested for lining the vaginal vault



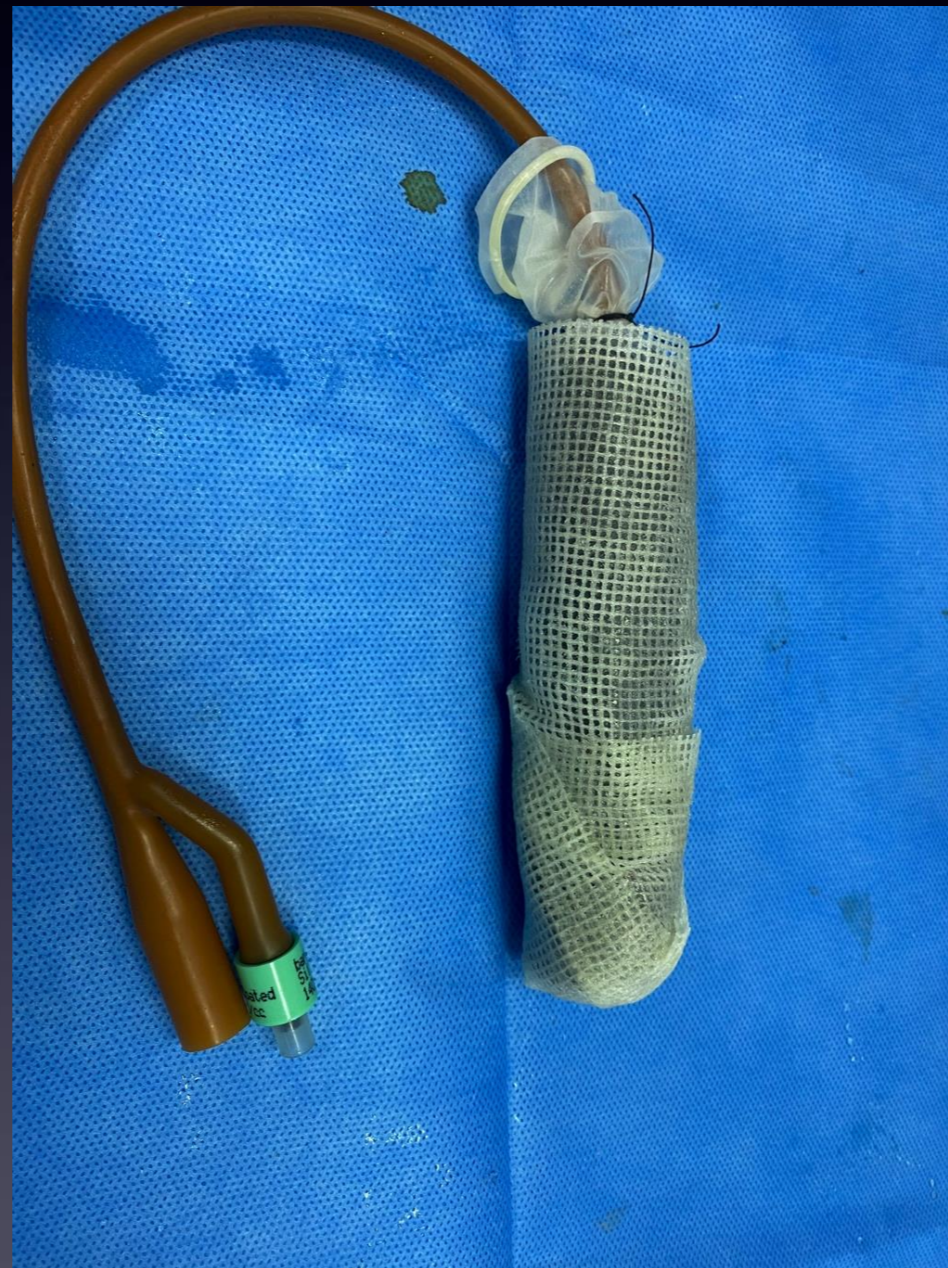Sponge and catheter used to make a special vaginal mould



Condom inseted over the mould and ready for use



Inlay dressing readied over the mould



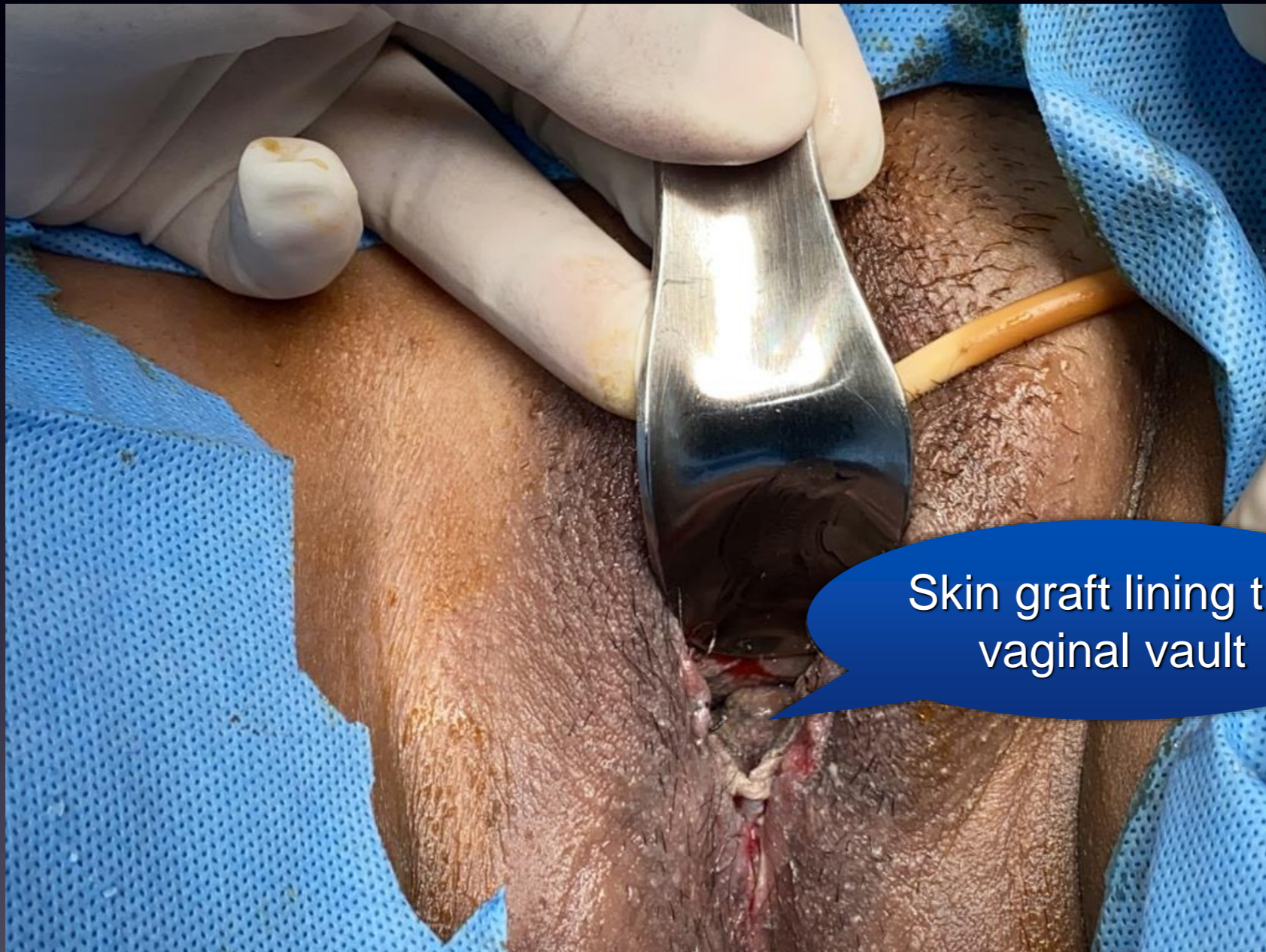Skin graft draped over the mould made for the new vaginal vault



Inlay graft is insetted into the new vaginal vault

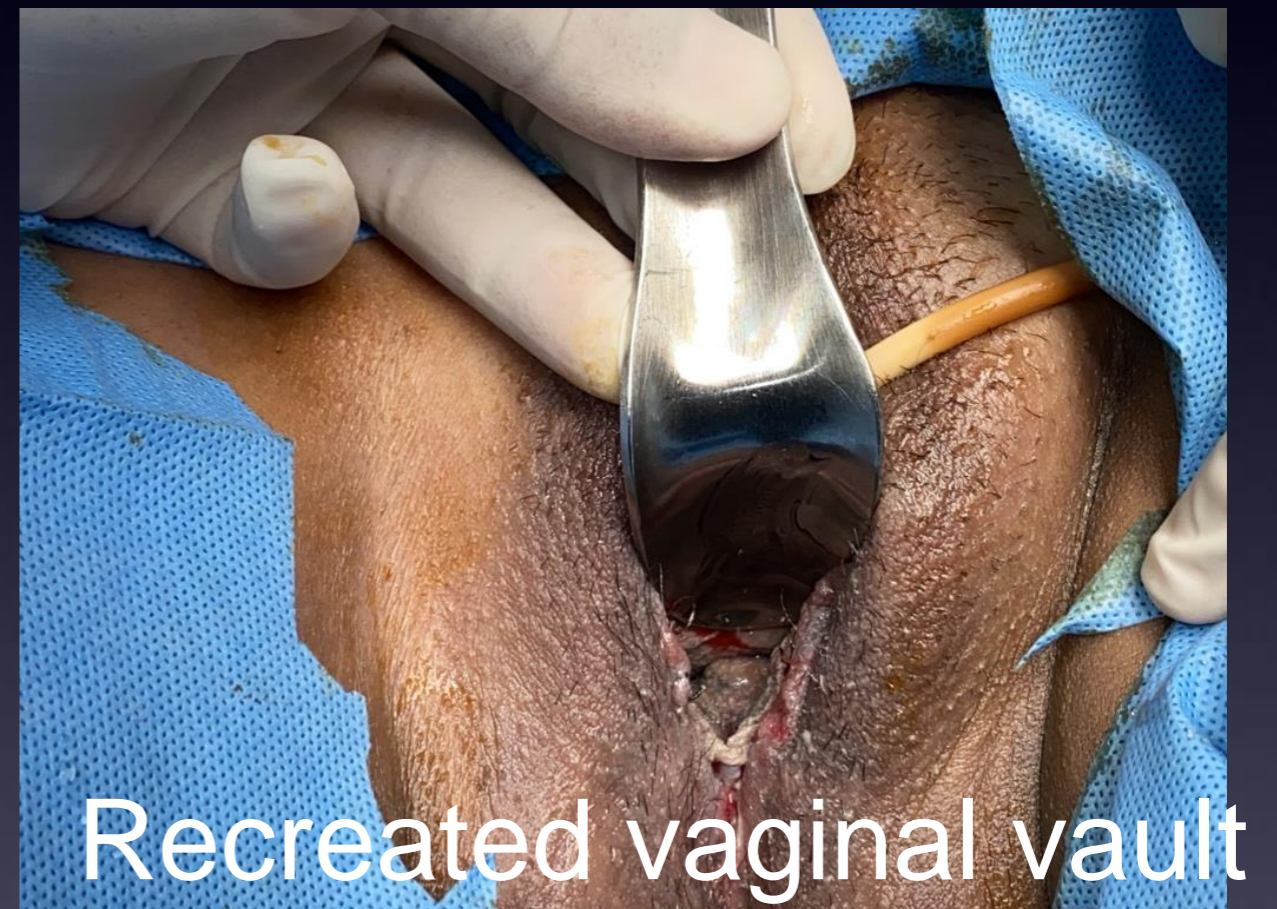
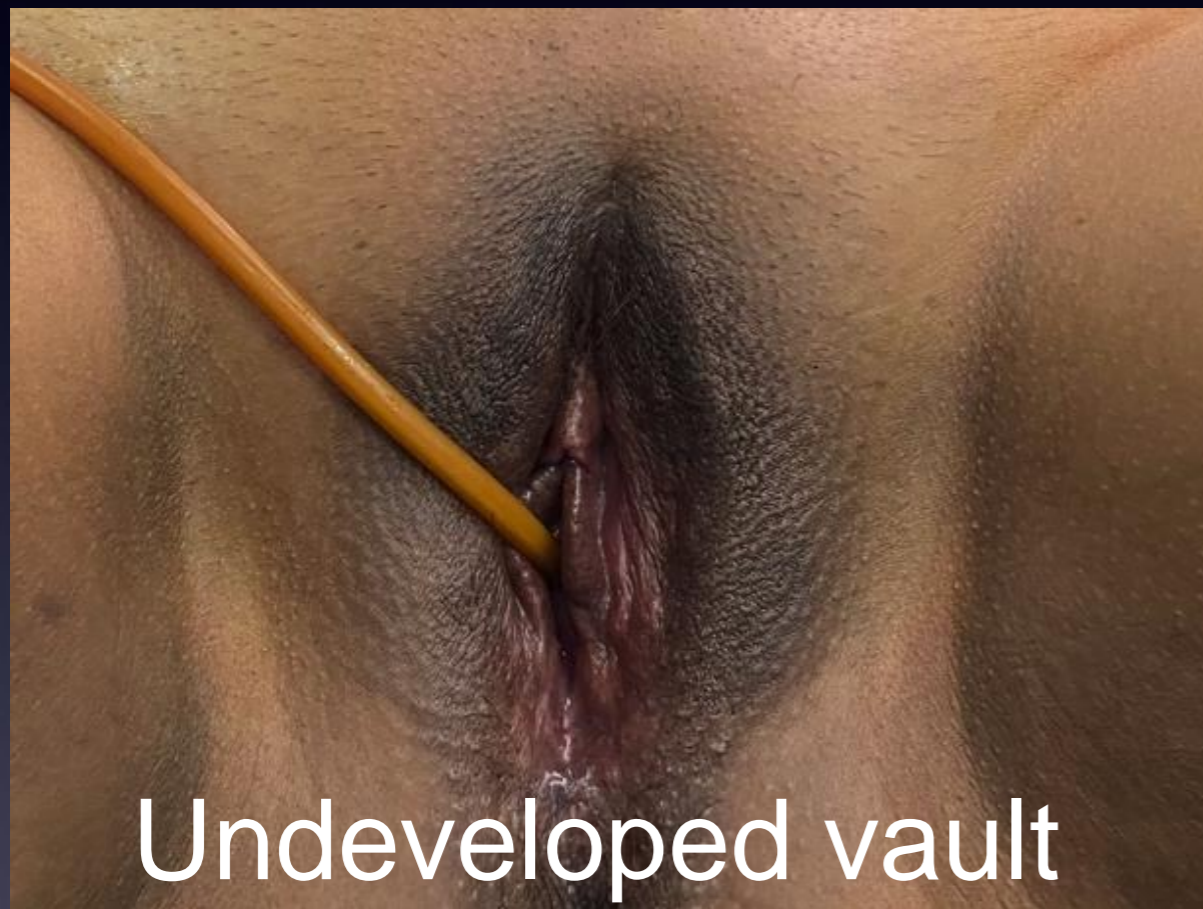
- Dressing with the mould insetted into the vault that is created
- Dressing left in place for 7 days
- After the first dressing a different mould is used to maintain the graft in position
- Graft settles in 2 weeks time
- Skin graft donor site heals in 2 weeks time

Newly created vault with skin graft lining



Skin graft lining the vaginal vault

Before and after the procedure



Post operative care involves regular use of a

- Dilators are to be used at least for 3 months
- Dilatation use to be continued till normal sexual activity resumes



A Clinique Belle Presentation
www.cliniquebelle.in